

Cytological evaluation of effusion fluid with cell block technique and cytology smears among Sudanese patients

Dr. ELSADIG A. ADAM

Assistant Professor, Elribat National University

NADIR ABASS AHMED MOHAMED ALI

MSc student, Histopathology Department

Faculty of Medical Laboratory Sciences

Al-Neelain University, Sudan

Abstract:

Background: *The cytological examinations of serous effusions have been well-accepted, and a positive diagnosis is often considered as a definitive diagnosis. It helps in staging, prognosis and management of the patients in malignancies and also gives information about various inflammatory and non-inflammatory lesions. Diagnostic problems arise in everyday practice to differentiate reactive atypical mesothelial cells and malignant cells by the routine conventional smear cytological smears method and cell block.*

Aims: *To compare the morphological features of the cytological smear method with those of the cell block method and also to assess the utility and sensitivity of the cell block method in the cytodiagnosis of serous effusions.*

Materials and Methods: *The study was conducted in the cytology section of the Department of Pathology. Serous fluid samples were subjected to diagnostic evaluation for over a period of 8months. Along with the conventional smears, cell blocks were prepared by using 10% alcohol-formalin as a fixative agent. Statistical analysis with the processing machine was performed to identify the cellularity, using the cytological smear and cell block methods.*

Results: a total of 60 patients attending military hospital and total lab care in Khartoum state in Sudan in period during from May 2014 to April 2015 were enrolled in this study. Their age ranges from 20-80 years. The utility of the cell block method in the cytodiagnosis of malignant effusions was found to be highly significant as compared to the Cell block method. The additional yield of malignancy was 10% more as was obtained by the Cell block method.

Cellularity and additional yield for malignancy was more sensitive and specific by the cell block method.

Cytology * NON RESULT

Cytology	NON RESULT		Total
	Positive	Negative	
Positive	15	3	18
Negative	2	37	39
Total	17	40	57

Sensitivity: = 93.75

Specificity = 92.5

Positive Predictive Value:0.88%

Negative Predictive Value: 0.94%

Cell_block * NON RESULT

cell_block	NON RESULT		Total
	Positive	Negative	
Positive	16	3	19
Negative	0	37	37
Total	16	40	56

Sensitivity: = 100.0%

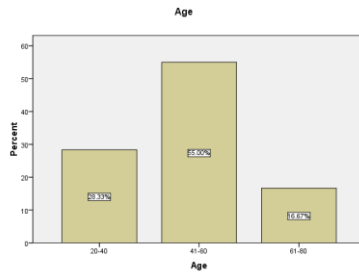
Specificity: = 92.5

Positive Predictive Value:84.2%

Negative Predictive Value: 100.0%

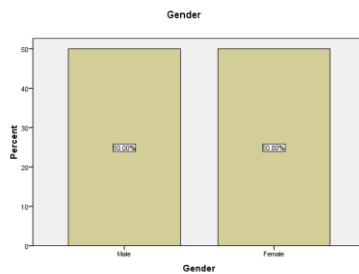
Age

		Frequency	Percent
Valid	20-40	17	28.3
	41-60	33	55.0
	61-80	10	16.7
	Total	60	100.0



Gender

	Frequency	Percent
Male	30	50.0
Female	30	50.0
Total	60	100.0



Conclusions: *The cell block method provides high cellularity, better architectural patterns, morphological features and an additional yield of malignant cells, and thereby, increases the sensitivity of the cytodiagnosis when compared with the cytological smears method.*

Key words: cytological evaluation, effusion fluid, cell block technique, cytology smears, Sudanese patients.

INTRODUCTION

Cytological study of serous infusion is a complete diagnostic modality. The information provided by serous fluid analysis serves several functions. First, it assists the clinician in formulating and pointing out the etiology of effusion and list of

differential diagnoses. Second, it allows one to follow the results of therapy and prognosis.

The accurate identification of cells as either malignant or reactive mesothelial cells is a diagnostic problem in conventional cytological smears. Distinguishing benign from malignant cellular changes may require meticulous screening, careful scrutiny of cellular features and an understanding of the range of reactive changes. Due to cellular overlapping, delaying artifact, suboptimal processing, preparatory cytotechnique and leaving behind useful material causes lower diagnostic yield in cytology smears method. This residual material can be very useful in increasing diagnostic yield by the cell block method. The cell block technique is one of the oldest and complementary methods for the evaluation of body cavity fluids. Cell block preparation increases the sensitivity of detecting malignancies, and also has the ability to reduce false-positive interpretations. A new method of cell block preparation by using 10% alcohol-acetic acid-formalin a fixative was used to identify the sensitivity of the diagnosis in comparison with the conventional smear cytological smears study. This method is so simple and inexpensive which requires no extra material compared to other methods. The main advantages of the cell block technique are preservation of tissue architecture.

MATERIALS AND METHODS

Pleural fluids were collected for cytological evaluation in the cytology section of the Department of Pathology, from May 2014 to April 2015 were enrolled in this study. Ten milliliters of fresh serous fluid sample was received. It was divided into two equal parts of five milliliters each. One part was subjected to conventional smear cytology and the other part for the cell block technique. The same sample was evaluated for a comparative study.

Conventional smear technique

The five milliliter sample was centrifuged at 2500 rpm for 15 minutes. A minimum of two thin smears were prepared from the sediment. One smear was prepared after air drying and stained with the May-Grünwald-Giemsa stain. The other smear was immediately fixed in 95% alcohol and stained with the Papanicolaou stain.

Cell block technique

The 5 mL sample that remained was subjected to fixation for one hour by mixing with 5 mL of 10% alcohol-formalin (i.e., nine parts of 90% alcohol and one part of 7.5% formalin). After one hour, this 10 ml fluid was centrifuged at 2500 rpm for 15 minutes. The supernatant was discarded and a further 3 mL of fresh 10% alcohol-formalin was once again added to the sediment and it was kept for one day. On the following day, the sediment containing the cell button of the pleural fluid sample was scooped out on to the filter paper and this cell button sediment sample was processed along with other routine histopathological specimens. The paraffin embedded cell button (cell block) sections of 4–6 μ thickness were prepared and stained with the hematoxylin and eosin stain. Special stains like the periodic acid Schiff (PAS) and mucicarmine were performed wherever necessary.

Interpretation of cytological smears versus Cell block

The samples were studied in detail taking into account the available clinical data, various investigation reports and morphological details. The samples were categorized as benign, suspicious for malignancy, or malignant lesions. The various morphological criteria that were taken into account included the cellularity, arrangement of the cells and the cytoplasmic and nuclear details. All these criteria were put together and used for classifying the various cytomorphological patterns. A

comparative evaluation of cytological smears versus cell block technique was conducted. The cytomorphological characters were studied to identify the malignancy and the most probable primary site.

METHODS

The present study was conducted on 60 patients who underwent paracentesis for the diagnosis of effusion cytology (Serous fluid) by cytological smears & cell block method. A total 60 serous fluid were received in the Cytopathology section, Department of Pathology, military hospital in Sudan, from May 2014 to April 2015. All the 60 fluid specimens were included in the study. Written informed consent of all the patients in the study was obtained. Clotted fluid specimen, time between collection and processing more than one hour and suboptimal preserved fluid specimens were excluded from our study. Thereafter, cytological diagnosis was made.

Ten milliliters of each fresh fluid specimen was divided into two equal parts of five milliliters each. One part was subjected to the conventional smear cytology technique and the other part for the cell block technique.

In conventional smear technique, the 5 milliliter fluid specimens were centrifuged at 2500 rpm for 10 minutes. A minimum of 3 smears were prepared from the sediment. One smear was prepared after air drying and it was stained with the May-Grünwald-Giemsa stain. The other two smears were immediately fixed in 95% alcohol, and were stained with the Papanicolaou stain and Haematoxylin-Eosin stain.

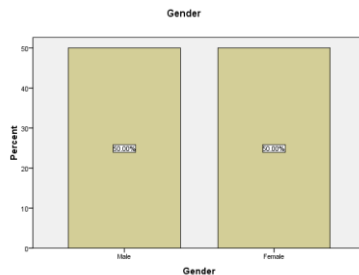
In cell block technique, we used AAF fixative (95% ethyl alcohol 34 ml + Glacial acetic acid 2 ml+ formalin 4 ml). After centrifugation at 2500 rpm for 10 minutes, cell sediment was formed. Cell sediment was mixed with thrice the volume of AAF fixative, and one or two drops of the mixture fluid was

centrifuged for 10 minutes at 2000 rpm. Again, re-suspended the cell button in AAF fixative and centrifuged for 10 minutes at 3000 rpm. The centrifuged tube was set aside undisturbed for 4 – 6 hours. The cell button was scraped out and wrapped in filter paper and processed in automatic tissue processor for routine histopathology section. The cell blocks were embedded in paraffin and sectioned at 4 µm thickness Thus, the same fluid specimen was evaluated for a comparative purpose.

All the 60 fluid specimens were subjected to the cytological smears and the Cell block techniques. It was then observed that out of total 60 specimens studied, years.

Table gender

	Frequency	Percent
Male	30	50.0
Female	30	50.0
Total	60	100.0



Distribution of number of fluid specimen among gender & type by conventional smear based diagnosis

Age * Cytology-Cellblock

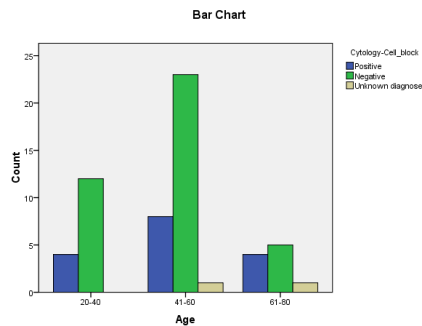
			Cytology-Cell_block			Total
			Positive	Negative	Unknown diagnose	
Age	20-40	Count	4	12	0	16
		% within Cytology-Cellblock	25.0%	30.0%	.0%	27.6%
		% of Total	6.9%	20.7%	.0%	27.6%
	41-60	Count	8	23	1	32

Elsadig A. Adam, Nadir Abass Ahmed Mohamed Ali- **Cytological evaluation of effusion fluid with cell block technique and cytology smears among Sudanese patients**

	61-80	% within Cytology-Cellblock	50.0%	57.5%	50.0%	55.2%
		% of Total	13.8%	39.7%	1.7%	55.2%
		Count	4	5	1	10
		% within Cytology-Cellblock	25.0%	12.5%	50.0%	17.2%
		% of Total	6.9%	8.6%	1.7%	17.2%
Total	Count	16	40	2	58	
	% within Cytology-Cellblock	100.0%	100.0%	100.0%	100.0%	
	% of Total	27.6%	69.0%	3.4%	100.0%	

Chi-Square Tests			
	Value	df	P-Value
Pearson Chi-Square	3.127 ^a	4	.537**
Likelihood Ratio	3.241	4	.518
Linear-by-Linear Association	.031	1	.861
N of Valid Cases	58		

**Not significant at the 0.05 level.



Sample types * Cytology-Cellblock

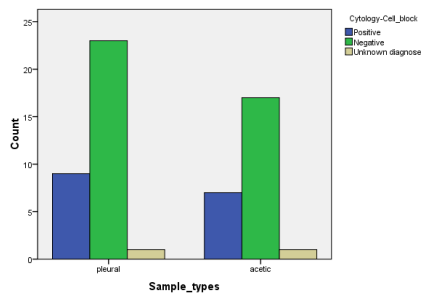
			Cytology-Cell_block			Total
			Positive	Negative	Unknown diagnose	
Sample types	pleural	Count	9	23	1	33
		% within Cytology-Cellblock	56.2%	57.5%	50.0%	56.9%
		% of Total	15.5%	39.7%	1.7%	56.9%
	acetic	Count	7	17	1	25
		% within Cytology-Cellblock	43.8%	42.5%	50.0%	43.1%
		% of Total	12.1%	29.3%	1.7%	43.1%
Total	Count	16	40	2	58	
	% within Cytology-	100.0%	100.0%	100.0%	100.0%	

Elsadig A. Adam, Nadir Abass Ahmed Mohamed Ali- **Cytological evaluation of effusion fluid with cell block technique and cytology smears among Sudanese patients**

	Cellblock				
	% of Total	27.6%	69.0%	3.4%	100.0%

Chi-Square Tests			
	Value	d-f	P-Value
Pearson Chi-Square	.047 ^a	2	.977**
Likelihood Ratio	.047	2	.977
Linear-by-Linear Association	.000	1	.986
N of Valid Cases	58		

**Not significant at the 0.05 level.

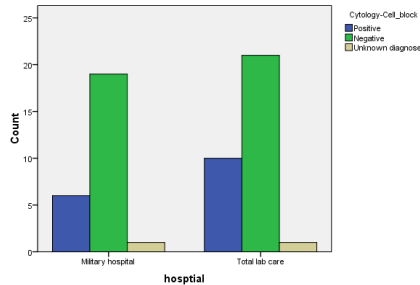


Hospital * Cytology-Cellblock

			Cytology-Cellblock			Total
			Positive	Negative	Unknown diagnose	
hospital	Military hospital	Count	6	19	1	26
		% within Cytology-Cellblock	37.5%	47.5%	50.0%	44.8%
		% of Total	10.3%	32.8%	1.7%	44.8%
	Total lab care	Count	10	21	1	32
		% within Cytology-Cellblock	62.5%	52.5%	50.0%	55.2%
		% of Total	17.2%	36.2%	1.7%	55.2%
Total		Count	16	40	2	58
		% within Cytology-Cellblock	100.0%	100.0%	100.0%	100.0%
		% of Total	27.6%	69.0%	3.4%	100.0%

Chi-Square Tests			
	Value	df	P-Value
Pearson Chi-Square	.484 ^a	2	.785**
Likelihood Ratio	.489	2	.783
Linear-by-Linear Association	.442	1	.506
N of Valid Cases	58		

**Not significant at the 0.05 level.



Distribution of number of fluid specimen among Benign, Suspicious of malignant & Malignant effusion by conventional smear cytological smears based diagnosis

By the Cell Block method, additional 60 cases were detected as malignant, that is a 10% more diagnostic yield for malignancy. Besides, 01 specimen was diagnosed as benign effusion by Cell Block method These 16 fluid specimens were reported as suspicious for malignancy by Cytological Smears method previously. Thus cellular yield which was obtained by the Cell Block method was more when it was compared to the one which was obtained by the Cytological Smears method. After Cell Block method was applied, diagnostic sensitivity and specificity increased.

Finally, after Cell Block method, of a total of 60. The malignant 26 cases of malignant effusions, total benin is 34 causes

CONVENTIONAL SMEAR TECHNIQUE

Cell block technique

The 5 mL sample that remained was subjected to fixation for one hour by mixing with 5 mL of 10% alcohol-formalin (i.e., nine parts of 90% alcohol and one part of 7.5% formalin). After one hour, this 10 ml fluid was centrifuged at 2500 rpm for 15 minutes. The supernatant was discarded and a further 3 mL of

fresh 10% alcohol–formalin was once again added to the sediment and it was kept for one day. On the following day, the sediment containing the cell button of the pleural fluid sample was scooped out on to the filter paper and this cell button sediment sample was processed along with other routine histopathological specimens. The paraffin embedded cell button (cell block) sections of 4–6 μ thickness were prepared and stained with the hematoxylin and eosin stain.

Interpretation of cytological Smears versus Cell Block

The samples were studied in detail taking into account the available clinical data, various investigation reports and morphological details. The samples were categorized as benign, suspicious for malignancy, or malignant lesions. The various morphological criteria that were taken into account included the cellularity, arrangement of the cells (acini, papillae and cell balls) and the cytoplasmic and nuclear details. All these criteria were put together and used for classifying the various cytomorphological patterns. A comparative evaluation of Cytological Smears versus Cell Block technique was conducted. The cytomorphological characters were studied to identify the malignancy and the most probable primary site. The samples were studied in detail taking into account the available clinical data, various investigation reports and morphological details. The samples were categorized as benign, suspicious for malignancy, or malignant lesions. The various morphological criteria that were taken into account included the cellularity, arrangement of the cells (acini, papillae and cell balls) and the cytoplasmic and nuclear details. All these criteria were put together and used for classifying the various cytomorphological patterns. A comparative evaluation of Cytological smears versus Cell Block technique was conducted. The cytomorphological characters were studied to identify the malignancy and the most probable primary site.

DISCUSSION

The cytological examination of serous effusions has increasingly gained acceptance in clinical medicine, to such an extent that a positive diagnosis is often considered the definitive test and obviates explorative surgery. It is important not only in the diagnosis of malignant lesions, but also helps in staging and prognosis.

The development of malignant serous effusion is a common complication of cancers like pulmonary and gastric carcinomas. Examination of fluids from the serous cavities of the body is an essential component of management in adult patients. Malignant neoplasms, especially lymphoid neoplasms, and in these cases cytological examination is very useful in their management.

One of the most common problems in Cytological smears cytology is to distinguish reactive mesothelial cells from metastatic neoplasms. The difficulty is either secondary to marked atypia of mesothelial cells caused by the microbiological, chemical, physical, immunological, or metabolic insults to the serous membranes or to the subtle cytomorphological features of some malignant neoplasms, particularly well-differentiated adenocarcinomas. The problem may become compounded by artifacts from poor fixation, preparation, or staining techniques. Although the preparation of Cytological Smears is a much simpler procedure than that of paraffin sections, it has limitations, that is, lack of tissue architecture. In some cases, appreciation of tissue architecture make diagnosis easier. Another limitation of the conventional cytological examination of effusions is that it has a sensitivity of only 40–70% for the presence of malignant disease due to overcrowding of cells, cell loss and different laboratory processing methods. Others like reactive mesothelial cells, abundance of inflammatory cells and paucity of representative

cells contribute to considerable difficulties in making conclusive diagnosis on conventional smears.

Since the introduction of the Cell Block technique by Bahrenburg nearly a century ago, it has been used routinely for processing fluids. In 1928, Zemansky concluded that the Cell Block method was superior to the Cytological Smears technique and that examination of materials. Cancer cells in the serous fluid are almost always indicative of metastatic cancer, as tumors arising from mesothelial cells lining these spaces are rare. When present, the tumor cells are usually numerous and frequently clusters may be found. The glandular forms are more reliable on Cell Block. Diagnostic problems arise whenever there is only marginal morphological distinction, for example, between reactive mesothelial cells and poorly differentiated malignant cells. Earlier methods of Cell Block preparations did not receive much attention, probably due to the lack of standardized technique. In fact the main problem with the Cell Block preparation is the risk of losing material during preparation. Some researchers used agar, plasma/thromboplastin to bind the sedimented cells, but they have some disadvantages.

The advantages of the CB procedure include:

1. Recognition of histological patterns of diseases that sometimes cannot be identified reliably in conventional smears.
2. Possible to study multiple sections by routine staining, special staining and immunocytological procedures.
3. Less cellular dispersal, which permits easier microscopic observation than do traditional smears.
4. Less difficulty in spite of background showing excess blood on microscopic observation.
5. Possibility of storing slides for retrospective studies. Storage of the CS is a practical problem.