

Antiteratogenic Property of *Syzygium cumini* (L.) Skeels (Duhat) Fruit Extract against Nicotine- Induced *Anas platyrhynchos* Linn. (Duck) Embryo

CARMELITA P. MAPANAO

Faculty, Department of Biology, College of Science
Polytechnic University of the Philippines
Sta. Mesa, Manila, Philippines

ARIANNE P. LOBA

ROSSELLE JOYCE D. DESALES

BS Biology, Department of Biology, College of Science
Polytechnic University of the Philippines
Sta. Mesa, Manila, Philippines

Abstract:

Studies are looking forward to medicinal plants in treating congenital malformations in newborn infants mostly caused by teratogenic exposure. One of the plants that exhibit pharmacological properties like antioxidant, antidiabetic, anti-inflammatory, diuretic, antiatherosclerotic, antihyperglycemic and antihyperlipidemic is Syzygium cumini (duhat). But despite of its benefits and properties, the fruit still remained underutilized in the country and no study claims that it is either a teratogen or has antiteratogenic property. Two crude extract of duhat fruit, using 70% ETOH and aqueous were evaluated for their antiteratogenic effect against nicotine. Duck embryo assay was used and different treatments were administered to the embryos. After two weeks of incubation, all the duck embryos were observed and gross morphological examination was done using morphometric analysis. Significant values were attained in most of the parameters by treatments when compared to the NIC group ($\alpha_{0.01} > 0.000$) except for the EDL and EDR parameters wherein only B2

($\alpha_{0.01} > 0.009$), and B3 ($\alpha_{0.01} > 0.003$). Results shows that treated embryos with mixed nicotine and duhat crude extract have fewer abnormalities compared to the positive control group wherein nicotine only was administered. Statistical analysis of the data shows that the potential antiteratogenic potential of duhat extract seems more effective in $100\mu\text{g/ml}$ in both ethanolic and aqueous extract. Based from the gathered results, the duhat crude extract extracted using 70% ETOH has higher yield of altering malformations caused by nicotine compared to duhat crude extract, extracted using aqueous solution.

Key words: Antiteratogenic, *Syzygium cumini*, *Anas platyrhynchos*

INTRODUCTION

Background of the Study

Teratogens are agents that cause negative effects on both prenatal and postnatal lives. They are agents that can cause abnormalities and such agents include drugs, chemical, infections, alcohol, and tobacco in different types of cigarette, pollutants, maternal health state, as well as maternal age and nutrition (Nwoke, 2008). Smoking is an important risk factor for the developing fetus during pregnancy (Memon and Pratten, 2013). Several studies have revealed that maternal smoking can cause low birth weight (Oster *et al.*, 1988), stillbirth and infant death (Wisborg *et al.*, 2000), congenital anomalies (Centers for Disease Control and Prevention, 2014) and neural tube defects (Kallen, 1998). The severity of birth defects caused by the consumption of nicotine during gestation varies depending on the exposure time, dosage amounts, maternal genetics and frequency of use.

A well-known substance with several teratogenic effects is nicotine (Inaloz *et al.*, 2000). Nicotine is a well-known alkaloid that is naturally occurring in some plants. There is considerable evidence that nicotine is present in human food, especially plants from the family Solanaceae such as potatoes,

tomatoes, eggplant and leaves of tobacco plant (Domino *et al.*, 1993; Centers for Disease Control and Prevention, 2013; Hossain and Salehuddin, 2013). It serves as a natural alternative to chemical pest control substances (Leyden *et al.*, 1999). It is present in the commercial tobacco plant which is the main ingredient in cigarettes (Hossain and Salehuddin, 2013).

Nicotine enters into the body either actively or passively through various modes of tobacco intake like snuffing, chewing and smoking (Chandrakar *et al.*, 2011). It could also be absorbed through inhalation, ingestion, skin contact and in mucous membranes (Centers for Disease Control and Prevention, 2013). Regardless of how nicotine is absorbed, it enters the bloodstreams where it circulates throughout the body and travels to the brain. Other sources of nicotine are man-made and include a variety of pharmaceutical products primarily intended to aid smoking cessation. These products include chewing gum, inhalers, nasal spray, transdermal patches, tablets and roll-on applications (Leyden *et al.*, 1999).

A significant portion of congenital malformations in newborn infants is caused by teratogenic exposure. In order to prevent them, it is necessary to find substances that can counteract the effects of teratogen. *Syzygium cumini* is native to the tropics that extends from Africa and Madagascar through southern Asia east through the Pacific. All parts of the *Syzygium cumini* can be used medicinally and it has a long tradition in alternative medicine. From all over the world, the fruits have been used for a wide variety of ailments, including cough, diabetes, dysentery, inflammation and ringworm (Reynertson *et al.*, 2005). From traditional practice, diverse studies arise and have formed the foundation of modern pharmacology. Various extracts of fruit of *Syzygium cumini* were found to have antidiabetic, anti-inflammatory, hepatoprotective, antihyperlipidemic, diuretic and antibacterial activities (Modi *et al.*, 2010). The development and

improvement brought by the different studies of *Syzygium cumini* fruit have led in determining its potential anti-teratogenic property a three day old *Anas platyrhynchos* embryo treated with nicotine.

Objectives of the Study

The study will determine the anti-teratogenic property of *Syzygium cumini* against nicotine-induced in *Anas platyrhynchos* embryo. The study specifically aims to:

1. determine the phytochemical constituents present in fruit ethanolic and aqueous extract of *Syzygium cumini*;
2. compare the efficacy of the two *Syzygium cumini* extracts (A = extract using 70% ETOH and B = extract using distilled water) in altering the effects of 100 μ l of 0.001% nicotine solution treated on a three (3) day old *Anas platyrhynchos*; and
3. identify and evaluate the morphological defects that can be prevented by *Syzygium cumini* fruit extract in the gross morphology of *Anas platyrhynchos* in terms of head, eye, culmen, neck, body, leg, wing and mass

Significance of the Study

Nicotine exposure during pregnancy poses significant health risks to the mother and the baby. Inhaling tobacco smoke from either passive or active smoking is the main source of nicotine exposure for the general population. This study provides information and awareness of health effects and health risks to everybody especially to women exposed to nicotine during pregnancy.

Although there are several properties of *Syzygium cumini* fruit extract that have been studied, there is no study available claiming that its extract has an anti-teratogenic effect. By having to identify and determine its potential anti-

teratogenic property, researchers will benefit the study with wide range of application that could be relevant for drug development and high value product.

Syzygium cumini fruit extract and the associated residual remnants of membranes resulting from extraction represent a significant disposal problem especially in those regions where *Syzygium cumini* cultivation is a major industry. This study is a valuable source in utilizing fruit remnants to reduce waste impact and environmental problem.

Scope and Limitation

The study was limited in knowing the antiteratogenic potential of *Syzygium cumini* against nicotine. It covered the treatment, incubation and evaluation of altered abnormalities by *Syzygium cumini* fruit extract against nicotine. Phytochemical screening was performed to evaluate the bioactive profile of the fruit extract. However, there was no isolation of active compounds from the extract itself.

There were fifteen (15) treatments in this study that were administered in fertilized three (3) day old *Anas platyrhynchos* embryos and for each treatment there were five (5) replicates which were done in three (3) trials. In the control group, the first treatment has undergone normal incubation (NT) and the second was treated with Phosphate-Buffered Saline (PBS). The positive control group was treated with 100µl of 0.001% nicotine solution. The fourth were treated with *Syzygium cumini* extract A which was extracted using 70% ETOH in different concentrations from 25 µg/ml, 50 µg/ml and 100 µg/ml which were labeled (A1, A2 and A3) respectively. The fifth treatment was the same with the fourth except that *Syzygium cumini* extract B was extracted by distilled water with concentrations from 25 µg/ml, 50 µg/ml and 100 µg/ml which were labeled (B1, B2 and B3). The sixth treatment was treated with mixtures of nicotine solution and *Syzygium cumini*

extract A labeled as (AN1, AN2 and AN3); same goes with the last treatment with nicotine solution and *Syzygium cumini* extract B labeled as (BN1, BN2 and BN3). Gross morphological development and defects in the embryo were observed through morphometric analysis after fifteen (15) day incubation period. Parameters observed in the morphological development were head length, eye diameter, culmen length, neck length, body length, total body length, wing length, leg length and mass. The observed parameters were measured using a vernier caliper in the nearest millimeter and mass was determined using weighing scale.

METHODOLOGY

1.0 Collection of Materials

1.1 Collection of Chemicals and Solutions

Nicotine stock solution was purchased from Belman Laboratories in Mandaluyong City. Chemicals that were used for making Phosphate Buffer Solution (NaCl, HCl, KCl, Na₂HPO₄, KH₂PO₄), phytochemical analysis (10% ferric chloride solution, Fehling's solution, dilute sulphuric acid, picric acid solution, 50% methanol solution metal magnesium, acetic anhydride, chloroform) and extraction (70% ethanol) were purchased in DKL Laboratory in Espana, Manila.

1.2 Collection and Identification of *Syzygium cumini*

Fresh *Syzygium cumini* fruits were collected in Daet, Camarines Norte. The fruits were washed with tap water and twice using distilled water to remove dust and other external contaminant (Ahmad *et al.*, 2012).

The collected fruits were then authenticated in the Botany Division of National Museum, Manila.

1.3 Collection of Duck Eggs

Three (3) day old *Anas platyrhynchos* fertilized eggs were purchased from R&M Balut Industry in Pateros, Metro Manila. The purchased eggs were stored in a box covered by several newspapers to ensure viability of eggs (Abletis, 2011).

2.0 Preparation of *Syzygium cumini* Fruit Extract

Six (6) kilograms of fully ripe berries of *Syzygium cumini* were carefully selected and washed thoroughly in distilled water for 5 minutes. Three (3) kilograms fruit pulp were obtained when seeds of the ripe fruits were removed. Fruit pulp were softened by subjecting it into the blender, then extracted by subjecting 1kg of pulp to 1L of distilled water and 70% ethanol (Bimakr *et al.*, 2011 and Laghari *et al.*, 2011) respectively. The mixtures were filtered through Whatmann no. 1 filter paper and the squeezed marc was disregarded. The two extracts (aqueous and ethanolic) were then evaporated using rotary evaporator under reduced pressure at 60°C in Analytical Services Laboratory in Quezon City. After that, the extracts were placed in a sterile dark bottle and kept in the refrigerator until use (Hegazy and Ibrahim, 2012). Constant weight of the two extracts were also obtained.

3.0 Phytochemical Analysis of *Syzygium cumini* Fruit Extract

The extracts were analyzed following the procedures of Tariq and Reyaz (2013) to test for the alkaloids, saponins, tannins, terpenoids, flavonoids, glycosides, volatile oils and reducing sugar.

3.1 Saponins

Saponins was detected using froth test. One (1) gram of the sample was weighed in conical flask. Then, 10 ml of sterile distilled water was added to the sample and boiled for five (5)

minutes. The mixture was filtered and 2.5 ml of the filtrate was added to 10 ml sterile distilled water in a test tube. The test tube was vigorously shaken for 30 seconds and allowed to stand for 30 minutes. Honeycomb froth indicated the presence of saponins.

3.2 Tannins

A portion of the extract was diluted with water and three (3) to four (4) drops of 10% ferric chloride solution were added. A blue color indicated gallic tannin and green color indicated catecholic tannins.

3.3 Reducing Sugars

An aliquot of 0.5ml of plant extracts was added with 1ml of water and five (5) to eight (8) drops of Fehling's solution and were heated over water bath. Brick red precipitate indicated the presence of reducing sugars.

3.4 Glycosides

Twenty five (25 milliliter) of diluted sulphuric acid was added to 5ml extract in a test tube and boiled for 15 minutes. This was cooled and neutralized with 10%NaOH, then 5ml of Fehling's solution was added to the mixture. Red brownish precipitate indicated the presence of glycosides.

3.5 Alkaloids

Picric acid solution was added to 2ml of crude extract in a test tube. An orange coloration indicated the presence of alkaloids.

3.6 Flavonoids

Four (4) milliliter of the extract solution was treated with 1.5ml of 50% methanol solution. The solution was warmed and metal magnesium was added. To this solution, five (5) to six (6) drops of concentrated hydrochloric acid were added. Red color of the

solution indicated the presence of flavonoids and orange color for flavones.

3.7 Volatile Oils

Two (2) milliliter of the extract were added with 0.1ml diluted NaOH and a small quantity of diluted HCl. A white precipitate indicated the presence of volatile oils.

3.8 Terpenoids

Four (4) milligrams of the extract was treated with 0.5 ml of acetic anhydride and 0.5ml of chloroform. Then this was added with concentrated solution of sulphuric acid. Red violet color indicated the presence of terpenoids.

4.0 Preparation of Different Treatments

4.1 Phosphate Buffer Saline Solution

Phosphate buffered saline solution (PBS) is a non-toxic solution used in biological research. It helps in maintaining the constant pH. Thin film of PBS water binds to the surface of the solution which prevents it from denaturation. For a one (1) liter of PBS with pH 7.4, 8 g of NaCl was added to 800 ml of distilled water. 0.2 g of KCl was added to the solution together with 1.44 g of Na₂HPO₄ and 0.24 g of KH₂PO₄. The pH was then adjusted to 7.4 with HCl. Distilled water was added to make a total volume of 1 liter (Sambrook *et al.*, 1989).

As a negative control, 0.2 ml of PBS was injected to the air cell of duck egg and was labeled as PBS. It also served as diluents to nicotine and extracts (Khaldoyanidi *et al.*, 2001).

4.2 Nicotine Treatment

One (1) ml of aliquot of 99% nicotine was diluted to 1000ml PBS to make 0.001% nicotine solution. 100µl of 0.001% nicotine

solution was used as positive control (Chandrakar *et al.*, 2011). This treatment was labeled as (NIC).

4.3 *Syzygium cumini* Fruit Extract Treatment

2.5 mg, 5.0 mg and 10.0 mg of each *Syzygium cumini* extracts (extracts using 70% ETOH and distilled water) were weighed and diluted in beaker with 100ml PBS to produce dosage of 25µg/ml, 50µg/ml and 100µg/ml respectively. Treatments with *Syzygium cumini* using 70% ETOH were labeled as A and treatments with *Syzygium cumini* using distilled water were labeled B. Dosage of 25µg/ml, 50µg/ml and 100µg/ml were labeled as 1, 2 and 3 respectively having A1, A2, A3, B1, B2, and B3.

4.4 *Syzygium cumini* Fruit Extract and Nicotine Treatment

To test for the anti-teratogenicity potential of *Syzygium cumini* aqueous and ethanolic extract against teratogen nicotine, 0.2ml of 25µg/ml, 50µg/ml and 100µg/ml were combined individually in respective test tubes with 100µl of 0.001% nicotine solution. Afterwards, the solutions were injected into the air cell of three (3) day duck embryo. These were labeled under treatments AN1, AN2, AN3, BN1, BN2 and BN3.

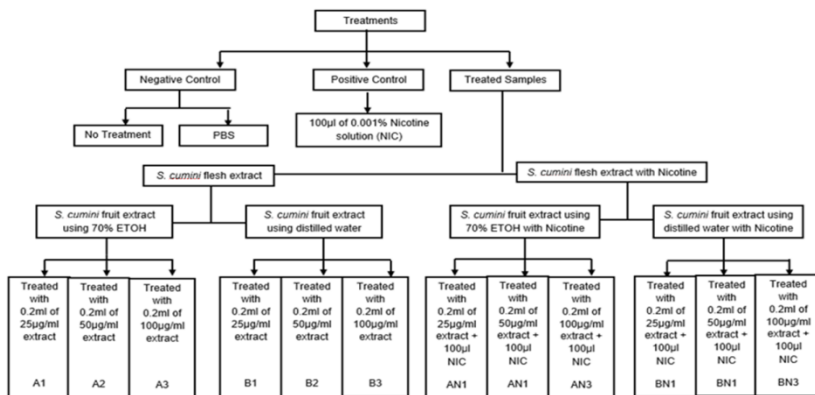


Figure 1. Summary of the Different Treatments

5.0. Biological Assay

5.1 Egg Candling

Candling is the process of holding a strong light above or below the egg to observe the embryo (FAO Corporate Document Repository, 2014) and to separate infertile eggs from fertile one. Eggs were candled to determine the condition of the air cell, yolk and white. In this study, used duck embryos were candled before inoculation of treatments and after 15 day of incubation.

5.2 Pre-inoculation and Inoculation Procedure

The purchased three (3) day old *Anas platyrhynchos* fertilized eggs were surfaced sterilized with 70% alcohol to avoid contaminants. A hole was made within the area of the air cell with a sharp and thick sterile lancet (Dalgic *et al.*, 2009). There were fifteen (15) treatments (NT, PBS, NIC, A1, A2, A3, B1, B2, B3, AN1, AN2, AN3, BN1, BN2 and BN3) with five (5) samples for each replicates and were done in (3) trials. For the negative control group, the first set up was the normal incubation, without chemical or *Syzygium cumini* extract, and the second set up only contained 0.2 ml PBS. For the positive control group, it was treated with 100µl of 0.001% nicotine solution. Afterwards, different treatments were introduced to each corresponding eggs by using 1cc luer syringes (Miller *et al.*, 2001). After treatments were administered, a strip of conventional micropore were used to cover the hole where the injection was made (Boulland *et al.*, 2010). The eggs were then labeled in the outer shell according to the injected treatments. The eggs that were treated were brought in R&M Balut Industry in Pateros, Metro Manila to be incubated at 37°C for fifteen (15) days (Chandrakar *et al.*, 2011).

5.3 Embryo Collection

The embryos were exposed after fifteen (15) days of incubation. The shells were chipped to create a wide opening for visualization of the embryo. The embryos were transferred to petri dishes for careful dissection of the allantoic stalk and other embryonic structure. Preservation of duck embryos were done using 10% formalin (Dalgic *et al.*, 2009).

5.4 Morphometric Analysis of *Anas platyrhynchos* embryo

Morphometric is one of the most dynamic and popular fields on the contemporary biological scene. It focuses on the quantitative characterization and analysis of morphological data (Elewa, 2004). There were nine (9) morphological characters that were analyzed and measured in this study namely head length, eye diameter, culmen length, neck length, body length, total body length, wing length, leg length and mass.

Morphometric analysis of body measurements of the duck embryo were taken as suggested by (Ojedapo *et al.*, 2012; Francesch *et al.*, 2011; Gueye *et al.*, 1998; Solomon, 1996; and Ceballos *et al.*, 1989). Head length was measured from the tip of the bill to the back of the embryo's skull. Eye diameter was measured from its widest part. Culmen length was measured by gently placing the caliper jaw against the base of the skull or feathering where the measurement starts then slide the inner caliper jaw until it just contacts the distal tip of the bill. Neck length was measured from occipital condyle to the cephalic borders of the caracoids. Body length was measured from the base of the neck down to its tail. Total body length was measured from head of embryo to its tail. Wing length was taken from the distal portion of the carpus to the tip of the longest primary feather. Leg length was measured from tibia to the tip of the claw. Embryo mass was determined using weighing scale.

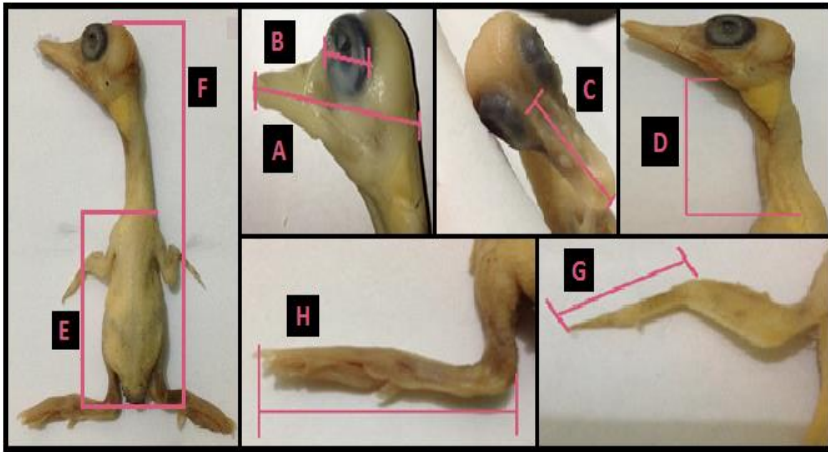


Figure 2. Measurements of duck embryos. (A) head length; (B) eye diameter; (C) culmen length; (D) neck length; (E) body length; (F) total body length; (G) wing length; and (H) leg length

6.0 Statistical Analysis

Gathered data were statistically analyzed using Kruskal-Wallis Test. Mann-Whitney U Test was used to compare the differences among varieties of means.

RESULTS AND DISCUSSIONS

Percentage Yield

The concentrated duhat extract produced 71.0 g and 21.0 g crude extract with aqueous and 70% ethanol respectively. Aqueous crude extract has a total percentage yield of 7.1% while the ethanolic crude extract has 2.1%. The extract appeared as a solid paste with deep purple or black color and has a pleasant smell. The crude extracts were prepared at varied concentrations and were tested for presence of the different phytochemical constituents.

Phytochemical Screening

In the study, the phytochemical screening was performed with aqueous and ethanolic extracts of the fruit of *Syzygium cumini*. The fruits of *S. cumini* were rich in saponins, tannins, reducing sugar, glycosides, alkaloids, flavonoids and terpenoids. The various phytochemical compounds detected are known to have beneficial importance in medicinal sciences. Based on the study conducted by Price *et al.* (1986), they stated that the primary action of saponins on cells cause a general increase in the permeability of the plasma membrane that makes it an effective barrier against noxious agents like nicotine especially at very high dose. Johnson *et al.*, (2006) found that some saponins increase the permeability of intestinal mucosal cells in vitro, and inhibit active mucosal transport and facilitate uptake of substances that are normally not absorbed. Studies have illustrated the beneficial effects of saponins on blood cholesterol levels, cancer, bone health and stimulation of the immune system. Tannins were reported to have anticarcinogenic and antimutagenic potentials which may be related to their antioxidative property according to Chung *et al.*, (1998). Also, it has a protective effect against nicotine since nicotine has a cancer causing property. Alkaloids with biological activity in humans affect the nervous system, particularly the action of chemical transmitters. It has been stated in one of the studies of Roja and Heble (1994) that alkaloids in duhat fruits has cancer chemopreventive action that can block, reverse or delays carcinogenesis before a development of a certain disease (Swami *et al.*, 2012). It is also widely used because of its pharmacological activities including antihypersensitive effects, antiarrhythmic effects, antimalarial activity, anticancer actions, and antibiotic activities as stated by Saxena *et al.* (2013). The flavonoids have been referred to as nature's biological response modifiers, because of their inherent ability to modify the body's reaction to allergies and virus and their

anti-allergic, antiinflammatory, anti-microbial and anti-cancer activities (Aiyelaagbe and Osamudiamen, 2009). Many researches have stated that flavonoids exhibit vasodilating action wherein it prevents the constriction of blood vessels whenever exposed to nicotine (Pietta, 2000). The terpenoids group show significant pharmacological activities, such as anti-viral, anti-bacterial, anti-malarial, anti-inflammatory, inhibition of cholesterol synthesis and anti-cancer activities (Mahato and Sen, 1997). Studies suggested that long term consumption of diets rich in plant polyphenols offered some protection against development of cancers, cardiovascular diseases, and diabetes, osteoporosis and neurodegenerative diseases (Pandey and Rizvi, 2009).

Table 1. Phytochemical constituents of *Syzygium cumini* fruit extract

Phytochemical constituent	ETOH	Aq
Saponins	+	+
Tannins	+	+
Reducing Sugars	+	-
Glycosides	+	-
Alkaloids	+	+
Flavonoids	+	+
Volatile Oil	-	-
Terpenoids	+	+

(+) Positive indicates presence of the phytoconstituent; (-) negative indicates absence of the phytoconstituent

Morphological Parameters

Head Length

The negative control treatment (NT and PBS) have a normal size of $30.30 \pm 0.20\text{mm}$ to $30.19 \pm 0.20\text{mm}$ respectively. As with A1 to A3 treatments, there were a slight increase of the head length compare to the NT and PBS, with a measurement of $30.72 \pm 0.21 \text{ mm}$, $31.74 \pm 0.15\text{mm}$, and 31.68 ± 0.12 respectively. It was observed in B1 to B3 treatments that the measurement of the head length was below the measurement in

the negative control treatment. The value of the measured head length was $30.07 \pm 0.15\text{mm}$, 30.08 ± 0.15 , and $30.09 \pm 0.18\text{mm}$ respectively. The data showed a significant decrease of the head length in the positive control treatment (NIC) of $22.03 \pm 1.39\text{mm}$. The head length measured in AN1 ($29.68 \pm 0.28\text{mm}$), AN2 ($29.51 \pm 0.42\text{mm}$), AN3 ($29.84 \pm 0.14\text{mm}$) was observed to have decreased with respect to the measurement of the negative control treatment. The measured head length of BN1, BN2, and BN3 treatments were $29.29 \pm 0.33\text{mm}$, $29.30 \pm 0.29\text{mm}$, $29.59 \pm 0.18\text{mm}$ respectively. The decrease in measurement was due to inducing the nicotine to the duck embryos together with the administration of the duhat crude extracts.

Multiple comparisons using the Mann-Whitney U Test showed that all of the negative control and treated groups were significant ($\alpha_{0.01} > 0.000$) on the measured head length of the duck embryo when compared to the NIC group. Other groups that contain significant values were the groups A1 ($\alpha_{0.01} > 0.004$), A2 ($\alpha_{0.01} > 0.000$) and A3 ($\alpha_{0.01} > 0.000$) when compared to the groups AN1, AN2, and AN3 respectively. This implies that the duhat extract altered the negative effects of nicotine in the head region.

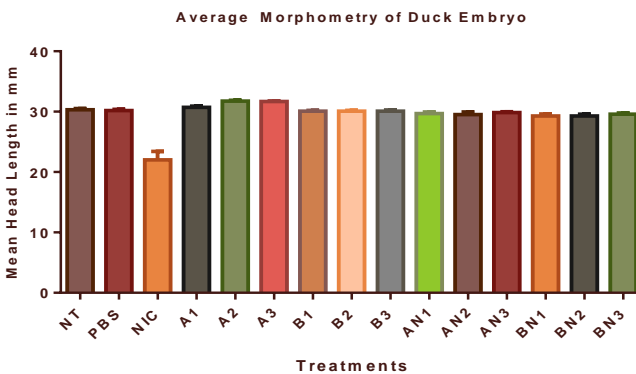


Figure 3. Effect of the different treatments to duck embryo's head length (HL).

Eye diameter

The treatments under negative control (NT and PBS) have a measurement of $8.22 \pm 0.07\text{mm}$ and $8.24 \pm 0.06\text{mm}$ respectively in the left side eye diameter. While a value of $8.26 \pm 0.07\text{mm}$ and $8.31 \pm 0.06\text{mm}$ was measured in the right side eye diameter. Measurement of the eye diameter in the A1 to A3 treatments as well as B1 to B3 treatments exceeded the eye diameter measured under the negative control treatments. For the left side eye diameter, values of $8.80 \pm 0.08\text{mm}$, $8.48 \pm 0.07\text{mm}$, and $8.60 \pm 0.09\text{mm}$ was measured in the duck embryos treated with A1, A2, and A3 treatments. Measurements of the right side eye diameter measured in the duck embryos treated with A1, A2, and A3 treatments were $8.81 \pm 0.09\text{mm}$, $8.51 \pm 0.06\text{mm}$, and $8.61 \pm 0.09\text{mm}$ respectively. With NIC treatment alone, the eye diameter went down to $7.71 \pm 0.30\text{mm}$ and $7.66 \pm 0.61\text{mm}$ on the left and right side respectively. AN1 to AN3 treatment has a value of $8.37 \pm 0.08\text{mm}$, $8.44 \pm 0.12\text{mm}$, and $8.63 \pm 0.08\text{mm}$ measured in the left side eye diameter respectively. Measured right side eye diameter of AN1 ($8.64 \pm 0.11\text{mm}$), AN2 ($8.65 \pm 0.17\text{mm}$) and AN3 ($8.69 \pm 0.04\text{mm}$) showed an increase in the measurement of the right side eye diameter in respect to the measurements in the negative control.

Results in the left side eye diameter showed that the only groups that contain significant values were B2 ($\alpha_{0.01} > 0.009$) and B3 ($\alpha_{0.01} > 0.003$) when compared to the NIC group. However, results in the right side eye diameter showed that there is no group that contains significant values when compared to NIC group. From this results, it can be inferred that only the Bx treatments showed efficacy in altering the malformations induced by nicotine.

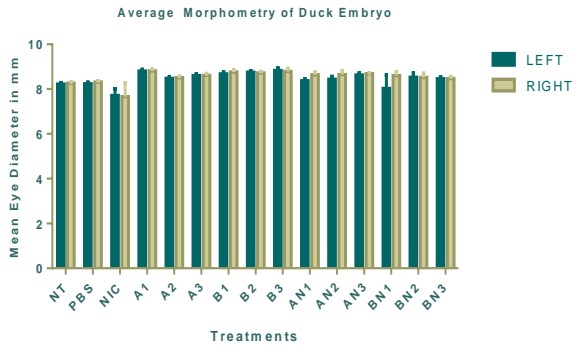


Figure 4. Effect of the different treatments to duck embryo’s eye diameter (EDL/EDR).

Culmen length

For the culmen length, values of $14.04 \pm 0.14\text{mm}$ and $13.92 \pm 0.13\text{mm}$ was measured in NT and PBS treatments. Measurements of $14.09 \pm 0.14\text{mm}$, $14.58 \pm 0.08\text{mm}$, and $14.69 \pm 0.08\text{mm}$ were measured in A1, A2, and A3 treatments. However, measurements in the B1 to B3 treatments is somehow below the NT value but still within the normal range. The measured culmen length in the duck embryos treated with B1, B2, and B3 were $13.82 \pm 0.18\text{mm}$, $13.85 \pm 0.12\text{mm}$ and $13.88 \pm 0.12\text{ mm}$ respectively. Again, another proof of negative effect of NIC, the culmen length was decreased to 8.84 ± 0.78 . The treatments mixed with nicotine showed lower measurements compared to the negative control treatment. The values measured in AN1, AN2, and AN3 were $12.96 \pm 0.24\text{mm}$, 13.17 ± 0.25 , and $13.50 \pm 0.13\text{mm}$ respectively. Values of $12.82 \pm 0.29\text{mm}$, 13.01 ± 0.21 , and $13.29 \pm 0.13\text{mm}$ were the measured culmen length of duck embryos under BN1, BN2, and BN3 treatments, respectively.

All the groups showed significant difference ($\alpha_{0.01} > 0.000$) in the beak length when compared to the NIC group. This implies that the duhat extract treatments altered the negative effects of nicotine in the beak region.

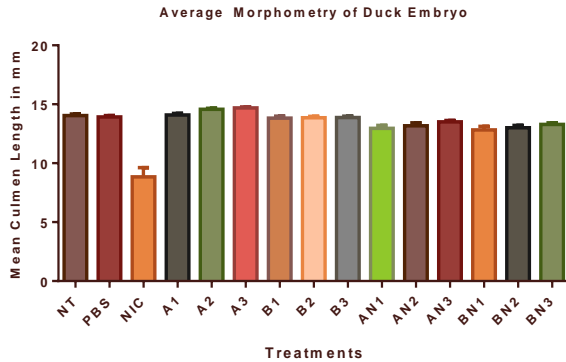


Figure 5. Effect of the different treatments to duck embryo’s culmen length (CL).

Neck length

The negative effect of NIC treatment was observed with the lowest measurement of 12.47 ± 1.77 mm was compared to the NT and PBS which has a measurement of 23.93 ± 0.22 mm and 23.91 ± 0.24 mm respectively. The duck embryos treated with duhat crude extract responded positively in the treatments administered. The measured culmen length were 24.46 ± 0.24 mm, 25.04 ± 0.35 mm, and 25.42 ± 0.30 mm for A1, A2, and A3 respectively. Mean values of AN1 (21.35 ± 0.67 mm), AN2 (21.5 ± 0.66 mm), AN3 (21.99 ± 0.27 mm), BN1 (21.99 ± 0.27 mm), BN2 (20.62 ± 0.43 mm) and BN3 (21.56 ± 0.44 mm) were observed to have decreased when compared to the Ax and Bx groups.

Results of the Mann-Whitney U test showed that were significant values ($\alpha_{0.01} > 0.000$) on the compared neck length of all the groups to the NIC group. The significant difference of all the groups compared to the NIC group implies that the duhat extract treatments were effective in altering the negative effects of nicotine in the neck region.

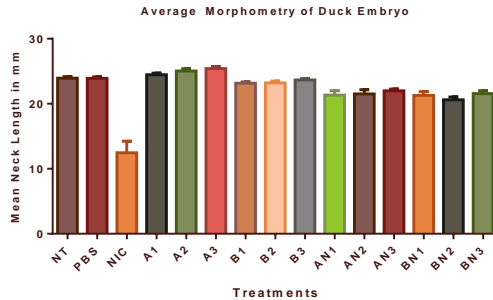


Figure 6. Effect of the different treatments to duck embryo’s neck length (NL).

Body length

The normal length of the body was observed in the NT and PBS group with mean values of 38.74 ± 0.43 mm and 38.24 ± 0.45 mm respectively. A positive result of the duhat crude extract was observed in A1 to A3 group wherein it has exceeded the normal measurement of the body length in the NT and PBS groups. Duck embryos treated with A1 has mean value of 39.18 ± 0.47 mm for the body length, those treated with A2 has 40.03 ± 0.41 mm and duck samples treated with A3 has 40.64 ± 0.29 mm. The B1 to B3 treatments were somehow below the NT value but still within the normal range. Mean values for the body length of the embryos treated with B1, B2, and B3 were 37.86 ± 0.23 mm, 38.11 ± 0.86 mm, and 37.80 ± 0.41 mm respectively. As for the NIC group, same observation as with the previous parts of the duck embryos, the measurement of the body length decreased to 22.52 ± 1.61 mm. In the AN1 to AN3 and BN1 to BN3 groups, it was observed that the measurement is below the normal body length but above the mean value observed in the NIC group. AN1 to AN3 and BN1 to BN3 groups have a measurement ranging from 36.61 ± 0.72 mm (AN1) to 37.66 ± 0.30 mm (AN3) and 36.64 ± 0.54 mm (BN1) to 37.44 ± 0.27 mm (BN3).

There were significant values ($\alpha_{0.01} > 0.000$) in all the groups when they were compared to the NIC group. The

significant difference of all the groups compared to NIC group showed the positive result of the duhat crude extract in preventing the negative effect of NIC.

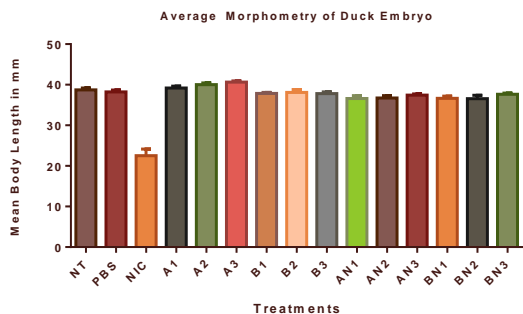


Figure 7. Effect of the different treatments to duck embryo's body length (BL).

Total body length

The total body length of duck embryos under NT and PBS group has a mean value of 80.61 ± 0.44 mm and 80.00 ± 0.30 mm respectively. The duck embryos under A1 to A3 treatments have a total body length that exceeded the measurement in the NT and PBS groups. Duck embryos under A1, A2, and A3 have mean values of 80.68 ± 0.40 mm, 81.48 ± 0.41 mm, and 82.42 ± 0.43 mm respectively. B1 to B3 treatments may have decreased the total body length of the duck embryos when compared to Ax and positive control treatments but the mean values were still within the normal range. Mean values of the total body length measured from duck embryos treated with Bx treatments were 79.74 ± 0.38 mm (B1), 79.26 ± 0.84 mm (B2), and 79.86 ± 0.53 mm (B3). As for the NIC group, the total body length decreased from 80.61 ± 0.44 mm (NT) to 49.86 ± 3.04 mm or almost 50% decrease compared to the normal value. However, mixed nicotine and ethanolic duhat crude extract (AN1, AN2, and AN3 treatments), and mixed nicotine and aqueous duhat crude extract (BN1, BN2, and BN3 treatments) improved the total

body length of the duck embryos from the mean value of 49.86 ± 3.04 mm (NIC alone) to a range of 76.54 ± 1.13 mm (AN1) to 78.14 ± 0.39 mm (AN3) and 76.77 ± 1.35 mm (BN1) to 77.92 ± 0.52 mm (BN3).

Statistical analysis showed that there is a significant difference ($\alpha_{0.01} > 0.000$) in the total body length of all the groups when they were compared to the NIC group. This showed the antiteratogenic potential of duhat extract against nicotine.

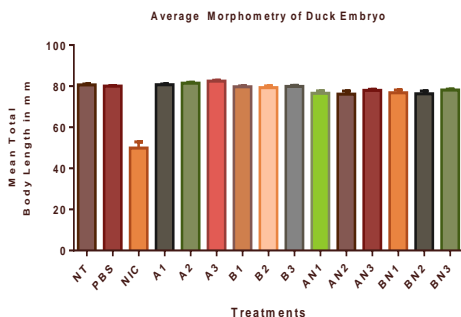


Figure 8. Effect of the different treatments to duck embryo's total body length (TBL).

Wing length

Next is the effect of different treatments to duck embryo's wing length (L/R).

Blue bar represents the left wing, while the violet is for the right wing of the duck. When it comes to the value at the left hand corner, the 1st details provided is for the left wing following by the measurement of the right wing. The mean values of the wing length in the NT and PBS groups ranges from (left wing) 12.38 ± 0.13 to 12.11 ± 0.14 and (right wing) 12.39 ± 0.13 mm to 12.12 ± 0.15 mm. There was an increase in measurement of the wing length when it comes to the Ax and Bx treatments for both left and right wing. Duck embryos under Ax treatments have mean values of (A1) 12.32 ± 0.12 and 12.32 ± 0.12 mm, (A2) 12.28 ± 0.15 and 12.29 ± 0.15 mm and (A3) 12.92 ± 0.11 and 12.93 ± 0.12 mm for the left and right

wing respectively. The Bx groups has a mean value of (B1) 12.15 ± 0.12 and 12.17 ± 0.13 mm, (B2) 12.55 ± 0.09 and 12.56 ± 0.10 mm and (B3) 12.22 ± 0.11 and 12.21 ± 0.11 mm for the left and right wing respectively. The NIC group has the lowest measurement, the left wing measured 8.39 ± 0.87 while the right wing length measured 8.14 ± 1.02 mm. Measurement of the left and right wing length of duck embryos subjected to ANx and BNx treatments were 11.64 ± 0.10 and 11.59 ± 0.13 mm (AN1), 11.53 ± 0.23 and 11.66 ± 0.22 mm (AN2), 1.70 ± 0.15 and 11.99 ± 0.15 mm (AN3), 11.37 ± 0.22 and 10.61 ± 0.80 mm (BN1), 11.65 ± 0.21 and 11.66 ± 0.22 mm (BN2), and 11.66 ± 0.11 and 11.73 ± 0.15 mm (BN3).

Results showed that were significant values ($\alpha_{0.01} > 0.000$) on the compared length on both left and right side of the wing in all the groups to the NIC group. The significant difference of all the groups compared to NIC group showed the activity of duhat crude extract in altering the malformations induced in the wing region by the nicotine treatment.

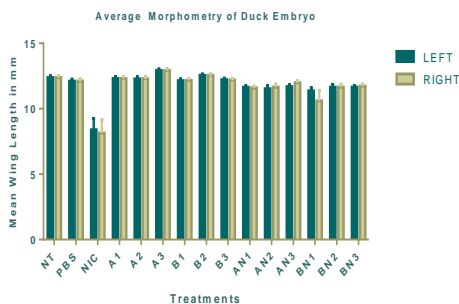


Figure 9. Effect of the different treatments to duck embryo's wing length (WLL/WLR).

Leg length

The leg length of the NT group has a mean value of 23.77 ± 0.28 (left) and 23.76 ± 0.28 mm (right) while the PBS group has a mean value of 23.31 ± 0.27 (left) and 23.29 ± 0.27 mm (right). Duck embryos administered with the NIC treatment has mean

values of 13.71 ± 1.92 (left leg) and 14.09 ± 1.87 mm (right leg). With the ethanolic and aqueous duhat extract administered, the leg length of the duck embryos exceeded the measurement in the NT and PBS groups. Duck embryos subjected to Ax treatments have mean values of (A1) 23.63 ± 0.12 and 23.66 ± 0.12 mm, (A2) 24.14 ± 0.28 and 24.07 ± 0.29 mm, and (A3) 24.30 ± 0.38 and 24.27 ± 0.39 mm while embryos subjected to Bx treatments have mean values of (B1) 23.42 ± 0.15 and 23.45 ± 0.16 mm, (B2) 24.09 ± 0.25 and 24.08 ± 0.25 mm, and (B3) 24.02 ± 0.22 and 24.06 ± 0.22 mm in the left and right wing. However, ANx and BNx groups has a lower measurement when compared to NT and PBS groups, but the measurements were way above the results of the NIC group. Duck embryos under ANx treatments have mean values for the leg length that ranges from 21.37 ± 0.28 to 21.85 ± 0.37 (left leg) and 21.53 ± 0.29 mm to 21.84 ± 0.36 mm (right leg). On the other hand, duck embryos under BNx treatments have mean values for the leg length that ranges from 20.94 ± 0.55 to 21.58 ± 0.43 (left leg) and 21.09 ± 0.55 mm to 21.66 ± 0.37 mm (right leg).

There were significant difference ($\alpha_{0.01} > 0.000$) on the compared length on both left and right side of the leg in all the groups to the NIC group. The significant difference of all the groups compared to NIC group showed the activity of duhat crude extract in altering the malformations induced in the leg region by the nicotine treatment.

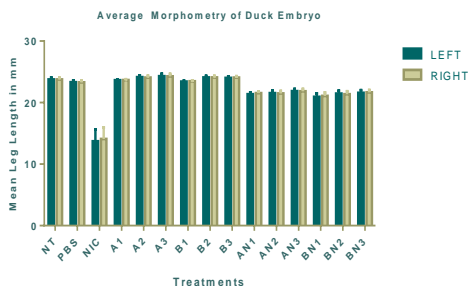


Figure 10. Effect of the different treatments to duck embryo's leg length (LLL/LLR).

Body Mass

As for the body mass, the NT and PBS groups has mean values of 10.48 ± 0.23 mm and 10.15 ± 0.12 mm respectively. The Ax and Bx groups exceeded the result of the NT and PBS groups. Duck embryos administered with Ax treatments has mean values for the body mass that ranges from 10.41 ± 0.20 mm to 11.79 ± 0.16 mm. On the other hand, Bx groups has mean values for the body mass that ranges from 10.03 ± 0.11 mm to 10.39 ± 0.20 mm. However, the measurement of the body mass of NIC group went down to 3.66 ± 0.59 mm or almost 70% decrease on the weight when compared to the negative control group. This is so far the lowest result for NIC compared to the other part of the duck embryo. The body mass somehow improved when ANx and BNx treatments were administered in the duck embryos. The AN3 group showed the highest increase in the body mass with a mean value of 10.06 ± 0.15 mm. BN3 has the highest mean value of 9.82 ± 0.14 mm when compared to other BNx groups.

All of the negative control and treated groups showed significant values ($\alpha 0.01 > 0.000$) on the measured body mass of the duck embryo when compared to the NIC group. This showed the activity of duhat crude extract in weight loss induced by the nicotine treatment.

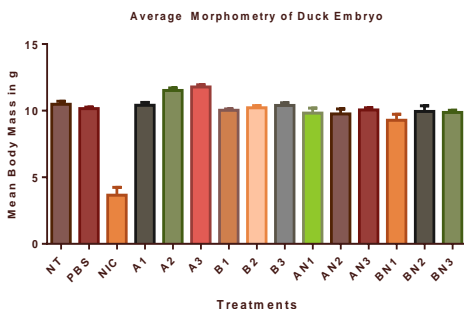


Figure 11. Effect of the different treatments to duck embryo's body mass (BM).

From the gathered data, it can be observed that there were differences in the morphological parameters measured on each group. This was supported when the data were run statistically, the effects of both ethanolic and aqueous *Syzygium cumini* extracts with nicotine showed significant difference in the embryos measured head width (HW), culmen length (CL), neck length (NL), body length (BL), total body length (TBL), left and right wing (WLL and WLR), left and right leg (LLL and LLR) and body mass (BM). The only morphological parameter that treatments did not show significant difference between the groups of treated duck embryo with nicotine and duhat crude extract, using 70% ETOH (AN1, AN2, and AN3 treatments) and the duck embryos treated with mixed nicotine and duhat crude extract using an aqueous solution, were the eye diameter (left and right). The two traits (EDL and EDR) were the only parameters that did not contain differences between the two groups ANx and BNx when they were being compared to the NIC group. To support the statistical data, the observed abnormalities were gathered. Kruskal-Wallis Test shows the duhat crude extract, using 70% ETOH (AN1, AN2, and AN3 treatments) has lower percentage of abnormalities found than the duck embryos treated with mixed nicotine and aqueous duhat extract (BN1, BN2, and BN3).

Reason behind this was due of the kind of extractant used, wherein 70% ETOH was more concentrated and has more yield of the extract obtained. Moreover, results showed that the reduction of abnormalities decreases as the dosage of both ANx and BNx treatments increased on treatments with nicotine. Results from multiple comparisons of all the treatments showed that both ethanolic and aqueous duhat extracts (A1, B1, B2, and B3) did not result statistically significant numbers when compared to the negative control groups (both the NT and PBS groups) except for A2 and A3; indicating that the extracts were nonteratogenic.

Significant values were attained in most of the parameters by treatments when compared to the NIC group ($\alpha_{0.01}>0.000$) except for the EDL and EDR parameters wherein only B2 ($\alpha_{0.01}>0.009$), and B3 ($\alpha_{0.01}>0.003$) groups showed significant difference.

Statistical analysis shows that the higher the concentration of the extract mixed with nicotine, the higher the possibility that it will get significant values when compared to the NIC group.

Table 2. The Average Morphological Traits Measured from the Duck Embryos in Different Treatments

Duck Embryo Body Parts	Treatments								
	NT	PBS	NICOTINE	A1	A2	A3	B1	B2	B3
	30.30 ± 0.20 ^a	30.19 ± 0.20 ^b	22.03 ± 1.39 ^c	30.72 ± 0.21 ^d	31.74 ± 0.15 ^e	31.68 ± 0.12 ^f	30.07 ± 0.15 ^g	30.08 ± 0.15 ^h	30.09 ± 0.18 ⁱ
*Head length	8.22 ± 0.07 ^a	8.24 ± 0.06 ^b	7.71 ± 0.30 ^c	8.80 ± 0.08 ^d	8.48 ± 0.07 ^e	8.60 ± 0.09 ^f	8.68 ± 0.09 ^g	8.75 ± 0.07 ^h	8.83 ± 0.11 ⁱ
*Eye Diameter (L)	8.26 ± 0.07 ^a	8.31 ± 0.06 ^b	7.66 ± 0.61 ^c	8.81 ± 0.09 ^d	8.51 ± 0.06 ^e	8.61 ± 0.09 ^f	8.76 ± 0.09 ^g	8.72 ± 0.07 ^h	8.79 ± 0.13 ⁱ
*Eye Diameter (R)	14.04 ± 0.14 ^a	13.92 ± 0.13 ^b	8.84 ± 0.78 ^c	14.09 ± 0.14 ^d	14.58 ± 0.08 ^e	14.69 ± 0.08 ^f	13.82 ± 0.18 ^g	13.85 ± 0.12 ^h	13.88 ± 0.12 ⁱ
*Culmen Length	23.93 ± 0.22 ^a	23.91 ± 0.24 ^b	12.47 ± 1.77 ^c	24.46 ± 0.24 ^d	25.04 ± 0.35 ^e	25.42 ± 0.30 ^f	23.17 ± 0.18 ^g	23.22 ± 0.26 ^h	23.65 ± 0.21 ⁱ
*Neck Length	38.74 ± 0.43 ^a	38.24 ± 0.45 ^b	22.52 ± 1.61 ^c	39.18 ± 0.47 ^d	40.03 ± 0.41 ^e	40.64 ± 0.29 ^f	37.86 ± 0.23 ^g	38.11 ± 0.86 ^h	37.80 ± 0.41 ⁱ
*Body Length	80.61 ± 0.44 ^a	80.00 ± 0.30 ^b	49.86 ± 3.04 ^c	80.68 ± 0.40 ^d	81.48 ± 0.41 ^e	82.42 ± 0.43 ^f	79.74 ± 0.38 ^g	79.26 ± 0.84 ^h	79.86 ± 0.53 ⁱ
*Total Body Length	12.38 ± 0.13 ^a	12.11 ± 0.14 ^b	8.39 ± 0.87 ^c	12.32 ± 0.12 ^d	12.28 ± 0.15 ^e	12.92 ± 0.11 ^f	12.15 ± 0.12 ^g	12.55 ± 0.09 ^h	12.22 ± 0.11 ⁱ
*Wing Length (L)	12.39 ± 0.13 ^a	12.12 ± 0.15 ^b	8.14 ± 1.02 ^c	12.32 ± 0.12 ^d	12.29 ± 0.15 ^e	12.93 ± 0.12 ^f	12.17 ± 0.13 ^g	12.56 ± 0.10 ^h	12.21 ± 0.11 ⁱ
*Wing Length (R)	23.77 ± 0.28 ^a	23.31 ± 0.27 ^b	13.71 ± 1.92 ^c	23.63 ± 0.12 ^d	24.14 ± 0.28 ^e	24.30 ± 0.38 ^f	23.42 ± 0.15 ^g	24.09 ± 0.25 ^h	24.02 ± 0.22 ⁱ
*Leg Length (L)	23.76 ± 0.28 ^a	23.29 ± 0.27 ^b	14.09 ± 1.87 ^c	23.66 ± 0.12 ^d	24.07 ± 0.29 ^e	24.27 ± 0.39 ^f	23.45 ± 0.16 ^g	24.08 ± 0.25 ^h	24.06 ± 0.22 ⁱ
*Leg Length (R)	10.48 ± 0.23 ^a	10.15 ± 0.12 ^b	3.66 ± 0.59 ^c	10.41 ± 0.20 ^d	11.52 ± 0.18 ^e	11.79 ± 0.16 ^f	10.03 ± 0.11 ^g	10.22 ± 0.17 ^h	10.39 ± 0.20 ⁱ
*Body Mass									

*Comparison of morphological character from the different treatments

*Values are reported as mean ± Standard error; means in columns followed by different superscripts are significantly different from each other.

Positive Control (Nicotine = 100µl of 0.001% Nicotine); Negative Control (NT = no treatment; PBS = contain 0.2ml Phosphate-Buffered Solution)

Syzygium cumini Extract

- A1 = 0.2ml of 25µg/ml *Syzygium cumini* extract using, 70% ETOH
- B1 = 0.2ml of 25µg/ml *Syzygium cumini* extract using aqueous
- A2 = 0.2 ml of 50µg/ml *Syzygium cumini* extract using, 70% ETOH
- B2 = 0.2ml of 50µg/ml *Syzygium cumini* extract using aqueous

Carmelita P. Mapanao, Arianne P. Loba, Rosselle Joyce D. Desales- **Antiteratogenic Property of *Syzygium cumini* (L.) Skeels (Duhat) Fruit Extract against Nicotine-Induced *Anas platyrhynchos* Linn. (Duck) Embryo**

A3 = 0.2ml of 100µg/ml *Syzygium cumini* extract using, 70% ETOH

B3 = 0.2ml of 100µg/ml *Syzygium cumini* extract using aqueous

Table 3. The Average Morphological Traits Measured from the Duck Embryos in Different Treatments

Duck Embryo Body Parts	Treatments			AN1	AN2	AN3	BN1	BN2	BN3
	NT	PBS	NICOTINE						
*Head length	30.30 ± 0.20 ^a	30.19 ± 0.20 ^b	22.03 ± 1.39 ^c	29.68 ± 0.28 ^d	29.51 ± 0.42 ^e	29.84 ± 0.14 ^f	29.29 ± 0.33 ^g	29.30 ± 0.29 ^h	29.59 ± 0.18 ⁱ
*Eye Diameter (L)	8.22 ± 0.07 ^a	8.24 ± 0.06 ^b	7.71 ± 0.30 ^c	8.37 ± 0.08 ^d	8.44 ± 0.12 ^e	8.63 ± 0.08 ^f	8.03 ± 0.60 ^g	8.53 ± 0.19 ^h	8.46 ± 0.09 ⁱ
*Eye Diameter (R)	8.26 ± 0.07 ^a	8.31 ± 0.06 ^b	7.66 ± 0.61 ^c	8.64 ± 0.11 ^d	8.65 ± 0.17 ^e	8.69 ± 0.04 ^f	8.60 ± 0.16 ^g	8.52 ± 0.18 ^h	8.47 ± 0.09 ⁱ
*Culmen Length	14.04 ± 0.14 ^a	13.92 ± 0.13 ^b	8.84 ± 0.78 ^c	12.96 ± 0.24 ^d	13.17 ± 0.25 ^e	13.50 ± 0.13 ^f	12.82 ± 0.29 ^g	13.01 ± 0.21 ^h	13.29 ± 0.13 ⁱ
*Neck Length	23.93 ± 0.22 ^a	23.91 ± 0.24 ^b	12.47 ± 1.77 ^c	21.35 ± 0.67 ^d	21.51 ± 0.66 ^e	21.99 ± 0.27 ^f	21.29 ± 0.57 ^g	20.62 ± 0.43 ^h	21.56 ± 0.44 ⁱ
*Body Length	38.74 ± 0.43 ^a	38.24 ± 0.45 ^b	22.52 ± 1.61 ^c	36.61 ± 0.72 ^d	36.72 ± 0.60 ^e	37.66 ± 0.30 ^f	36.64 ± 0.54 ^g	36.58 ± 0.83 ^h	37.44 ± 0.27 ⁱ
*Total Body Length	80.61 ± 0.44 ^a	80.00 ± 0.30 ^b	49.86 ± 3.04 ^c	76.54 ± 1.13 ^d	76.14 ± 1.48 ^e	78.14 ± 0.39 ^f	76.77 ± 1.35 ^g	76.33 ± 1.28 ^h	77.92 ± 0.52 ⁱ
*Wing Length (L)	12.38 ± 0.13 ^a	12.11 ± 0.14 ^b	8.39 ± 0.87 ^c	11.64 ± 0.10 ^d	11.53 ± 0.23 ^e	11.70 ± 0.15 ^f	11.37 ± 0.22 ^g	11.65 ± 0.21 ^h	11.66 ± 0.11 ⁱ
*Wing Length (R)	12.39 ± 0.13 ^a	12.12 ± 0.15 ^b	8.14 ± 1.02 ^c	11.59 ± 0.13 ^d	11.66 ± 0.22 ^e	11.99 ± 0.15 ^f	10.61 ± 0.80 ^g	11.66 ± 0.22 ^h	11.73 ± 0.15 ⁱ
*Leg Length (L)	23.77 ± 0.28 ^a	23.31 ± 0.27 ^b	13.71 ± 1.92 ^c	21.37 ± 0.28 ^d	21.53 ± 0.45 ^e	21.85 ± 0.37 ^f	20.94 ± 0.55 ^g	21.46 ± 0.49 ^h	21.58 ± 0.43 ⁱ
*Leg Length (R)	23.76 ± 0.28 ^a	23.29 ± 0.27 ^b	14.09 ± 1.87 ^c	21.53 ± 0.29 ^d	21.48 ± 0.42 ^e	21.84 ± 0.36 ^f	21.09 ± 0.55 ^g	21.35 ± 0.48 ^h	21.66 ± 0.37 ⁱ
*Body Mass	10.48 ± 0.23 ^a	10.15 ± 0.12 ^b	3.66 ± 0.59 ^c	9.82 ± 0.37 ^d	9.75 ± 0.38 ^e	10.06 ± 0.15 ^f	9.28 ± 0.46 ^g	9.87 ± 0.16 ^h	9.82 ± 0.14 ⁱ

*Comparison of morphological character from the different treatments

*Values are reported as mean ± Standard error; means in columns followed by different superscripts are significantly different from each other.

Positive Control (Nicotine = 100µl of 0.001% Nicotine); Negative Control (NT = no treatment; PBS = contain 0.2ml Phosphate-Buffered Solution)

Syzygium cumini Extract with 100µl of 0.001% Nicotine

AN1 = 0.2ml of 25µg/ml *Syzygium cumini* extract using, 70% ETOH

BN1 = 0.2ml of 25µg/ml *Syzygium cumini* extract using aqueous

AN2 = 0.2 ml of 50µg/ml *Syzygium cumini* extract using, 70% ETOH

BN2 = 0.2ml of 50µg/ml *Syzygium cumini* extract using aqueous

AN3 = 0.2ml of 100µg/ml *Syzygium cumini* extract using, 70% ETOH

BN3 = 0.2ml of 100µg/ml *Syzygium cumini* extract using aqueous

Abnormality Occurrence

Positive Control

Embryos treated with Nicotine

The positive control group treated with nicotine was used as a standard for abnormal duck embryo development. Blood clotting in the head region were commonly observed in this group. Various embryo exhibited abnormalities such as microcephaly (93.33%), open brain (33.33%), and unnatural head orientation (66.67%). Most duck samples in this group have flat eyes (86.67%) and few have no eyelids (26.67%) while one of the duck sample exhibited the absence of an eye (6.67%). Almost all of the embryos in this group exhibited beak malformations. Short beak was observed in 93.33% of the embryos, curved beak was observed in 80% of the samples. Almost all of the embryos has shorter than normal neck (93.33%) while one exhibited longer than normal neck (6.67%) when compared to the neck measurements on the untreated group. 100% of the duck embryos was observed to exhibit unproportioned body while 73.33% has an exposed visceral organ. Some of the duck samples also exhibit white colored body (26.67%), while 20% have swollen body. The forelimbs of 66.67% of the embryos were observed to exhibit short wings while 46.67% have malformed wings. Most of the embryos exhibited short malformed legs (93.33%) while some were observed to have no legs (26.67%).

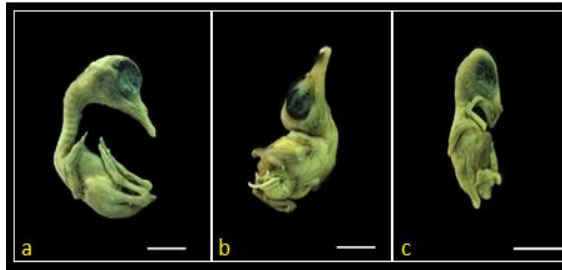


Figure 12. Photograph of an 18 day old duck embryos under the positive control group. (a)has flat eyes, no eyelids, malformed beak, (b) has unnatural head orientation, microcephaly, short neck (c) has microcephaly, flat eyes, no eyelids, malformed beak, short neck, and blood clot in the body. Scale bar = 15mm

Negative Control

Untreated Duck Embryo

No treatment was administered in this group that was used as a standard for normal duck embryo development. After fifteen days of incubation, duck samples in this group were found to exhibit no abnormalities.

Embryos treated with Phosphate Buffer Solution

The PBS group was another negative control group which also served as a standard for normal duck embryo development. This group was also found to develop normally and with no abnormalities.

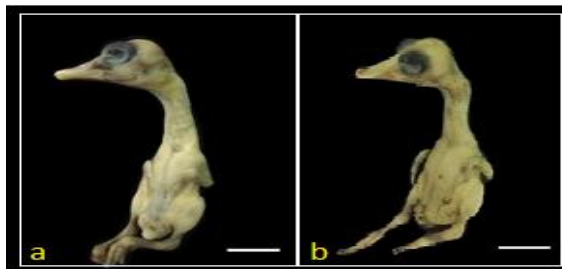


Figure 13. Photograph of an 18 day old duck embryos under the negative control group. Embryos under this group contain no morphological defects nor abnormalities (a) belongs to the untreated group (NT); (b) belongs to the group with Phosphate Buffered Saline (PBS). Scale bar = 15mm

Duck Embryos treated with *Syzygium cumini* Ethanolic Extract Only

Duck embryos developed normally upon administration of the Ax treatments and no abnormalities were observed.

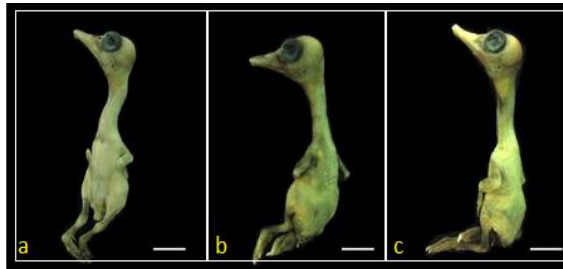


Figure 14. Photograph of 18 day old duck embryos treated with *Syzygium cumini* extract using 70% ETOH. (a) Belongs to the group treated with 25µg/ml *Syzygium cumini* extract; (b) embryo under the group treated with 50µg/ml *Syzygium cumini* extract; (c) under the group with 100µg/ml *Syzygium cumini* extract. Scale bar = 15mm

Duck Embryos treated with *Syzygium cumini* Aqueous Extract Only

Same results were observed in the duck embryos that were subjected to Bx treatments. No abnormalities were observed in the embryos.

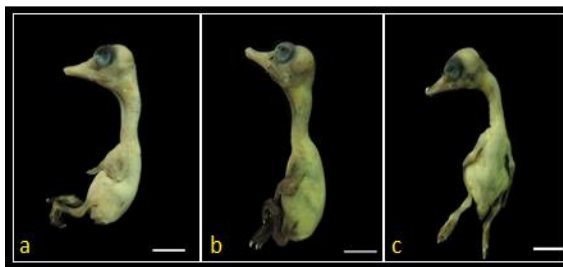


Figure 15. Photograph of 18 day old duck embryos treated with *Syzygium cumini* extract using aqueous. (a) Belongs to the group treated with 25µg/ml *Syzygium cumini* extract; (b) embryo under the group treated with 50µg/ml *Syzygium cumini* extract; (c) under the group with 100µg/ml *Syzygium cumini* extract. Scale bar = 15mm

Duck Embryos with Nicotine and *Syzygium cumini* Ethanolic Extract

Embryos treated with Nicotine and 25µg/ml *Syzygium cumini*, using 70% ETOH

The abnormalities observed in this group are the same with the positive control group but with lower occurrence. Various deformities in the head were observed in the duck embryos wherein 53.33% exhibited unnatural head orientation, 13.33% exhibited microcephaly, and 6.67% have an open brain. Flat eyes were observed in 26.67% of the embryos and some exhibited the absence of eyelids (13.33%). The beak was observed to be short in 40% of the samples while curved beak was observed in 13.33% of the samples. Abnormalities in the neck were observed to be twitched in 53.33% of the samples and a shorter neck when compared to the negative control group was observed in 66.67% of the embryos. There is a lower occurrence (20%) of unproportioned and swollen body in this group compared with the positive group. 26.67% of the embryos have wing malformations while 13.33% of the embryos have short wings when compared to the embryos under the negative control group. Shorter than normal leg length was also observed in 53.33% of the duck samples. Blood clotting in the body was observed 26.67% of the samples.

Embryos treated with Nicotine and 50µg/ml *Syzygium cumini*, using 70% ETOH

Half of the embryos in this group were observed to have unnatural head orientation (60%) and few exhibit microcephaly (20%). Flat eyes were observed in 13.33% of the embryos with lower occurrence compared to the embryos administered with A1 treatment. Malformations in the beak such as curved beak (13.33%) and short beak (26.67%) were observed in the embryos but with lower occurrence compared to the positive control

group and the A1 group. Abnormalities in the neck of 53.33% of the embryos in this group were also observed to be twitched and 40% have short neck. Few (26.67%) duck samples were observed to exhibit unproportioned and 13.33% have swollen body in this group. Malformations in the wing were observed in 13.33% of the embryos. Short legs were also observed in 46.67% of the duck samples. Lower occurrence (13.33%) of blood clotting in the body compared to NIC and AN1 group.

Embryos treated with Nicotine and 100µg/ml *Syzygium cumini*, using 70% ETOH

Fewer abnormalities were observed in this group compared to groups AN1 and AN2. No deformation was observed in the head. Flat eyes were observed in 13.33% of the duck embryos. The beak of 20% of the embryos was observed to be short and slightly curved. Abnormalities in the neck were also observed to be twitched in 53.33% of the embryos and short in 40% of the samples. 6.67% of the duck samples exhibited an unproportioned body in this group. The same 6.67% of the sample from this group exhibited a malformation in the wing. Short leg was also observed in 40% of the duck samples while 13.33% have blood clot in the body.

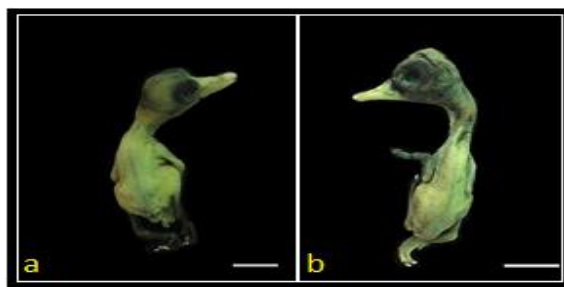


Figure 16. Photograph of 18 day old duck embryos treated with mixed nicotine and 25µg/ml *Syzygium cumini* using 70% ETOH. Both have blood clot in the head region and flat eyes. (a) Microcephaly, short neck, short wings and legs (b) open brain, no eyelids, twitched neck, and swollen body. Scale bar = 15mm

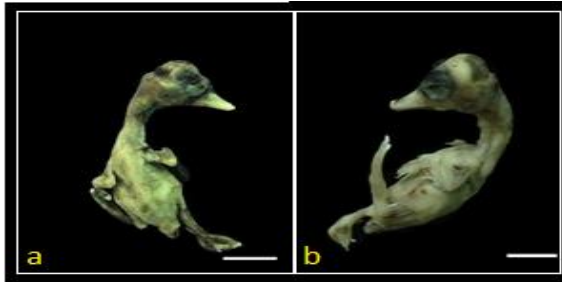


Figure 17. Photograph of 18 day old duck embryos treated with mixed nicotine and 50 μ g/ml *Syzygium cumini* using 70% ETOH. Both have blood clot in the head region and short beak. (a) Microcephaly, no eyelids and short wing (b) twitched neck. Scale bar = 15mm




Figure 18. Photograph of an 18 day old duck embryos treated with mixed nicotine and 100 μ g/ml *Syzygium cumini* using 70% ETOH. Both embryos have twitched neck. (a) malformed wing (b) flat eyes, short wing. Scale bar = 15mm

Duck Embryos with Nicotine and *Syzygium cumini* Aqueous Extract

Embryos treated with Nicotine and 25 μ g/ml *Syzygium cumini* using Aqueous

The embryos in this group exhibited abnormalities that were almost the same with AN1 group. Some have unnatural head orientation (40%) and others exhibit microcephaly (20%). Flat eyes were observed in 33.33% of the embryos while 6.67% was observed to exhibit the absence of an eye. Most of the embryos in this group have short beak (46.67%) while some have curved beak (13.33%). The neck of 46.67% was observed to be twitched

while 53.33% of the samples have shorter than normal neck when compared to the negative control group. Malformations in the body were observed in some of the duck embryos wherein such as white colored body (13.33%), unproportioned body (20%), and swollen body (13.33%). An embryo (6.67%) was observed to have no wing while 33.33% have short wings. Short legs was observed in 60% of the duck samples. 33.33% have blood clot in the head region while 26.67% were observed to have excessive weight loss when compared to the positive control and Bx groups.

Embryos treated with Nicotine and 50µg/ml *Syzygium cumini* using Aqueous

Head abnormalities have lower occurrence when compared to NIC and BN1 groups. Unnatural head orientation was observed in 20% of the embryos while 6.67% exhibit microcephaly and has an open brain. 13.33% of the samples have flat eyes while 6.67% was observed to exhibit the absence of an eyelid. There was lower occurrence of short and curved beak in this group when compared to the NIC and BN1 group. Short beak was observed in 33.33% of the embryos while 6.67% has curved beak. The embryos exhibited twitched neck (53.33%) that was while some have short neck (73.33%). Malformations such as white colored body (6.67%), unproportioned body (33.33%), and swollen body (20%) were observed in the duck embryos in this group. 20% of the samples have short wings while 13.33% have malformed wings. Short legs observed in 46.67% of the embryos, 20% have blood clot in the head region while others have excessive weight loss (33.33%) when compared to the positive control, Ax, and Bx groups.

Embryos treated with Nicotine and 100µg/ml *Syzygium cumini* using Aqueous

The embryos in this group exhibited fewer abnormalities (57%) compared with the BN1 and BN2 groups. Some embryos were observed to exhibit microcephaly (6.67%). Flat eyes were the only abnormality in the eye part that were observed in 26.67% of the embryos. Few embryos in this group have short beak (26.67%) while others have twitched neck (60%), and short neck (53.33%). One of the duck samples exhibit white colored body (6.67%) and some have swollen body (13.33%). An embryo was observed to have malformed wing (6.67%) while some have short wings (13.33%). Short legs were observed 53.33% of the duck samples and 6.67% have a malformed leg. Only 20% of the samples have blood clot in the head region.

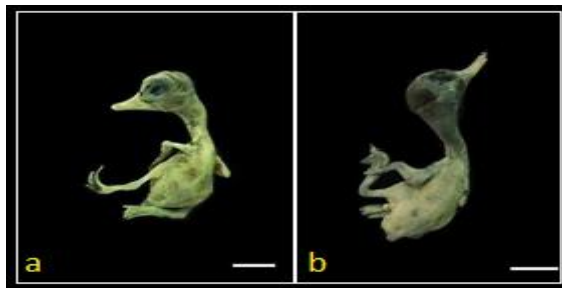


Figure 19. Photograph of 18 day old duck embryos treated with mixed nicotine and 25µg/ml *Syzygium cumini* using aqueous. Both have microcephaly and flat eyes (a) no eyelids, twitched neck, short beak and wing (b) blood clot in the head region, curved beak, and white colored body. Scale bar = 15mm

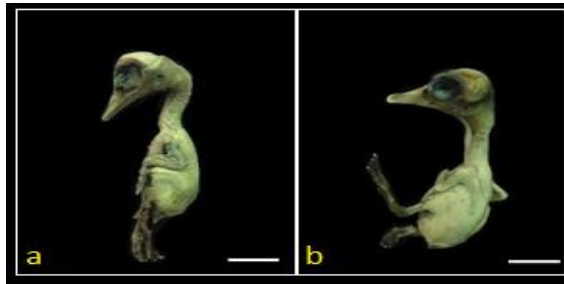


Figure 20. Photograph of 18 day old duck embryos treated with mixed nicotine and 50µg/ml *Syzygium cumini* using aqueous. (a) open brain, flat eyes, twitched neck (b) flat eyes, blood clot in the head region and white colored body. Scale bar = 15mm

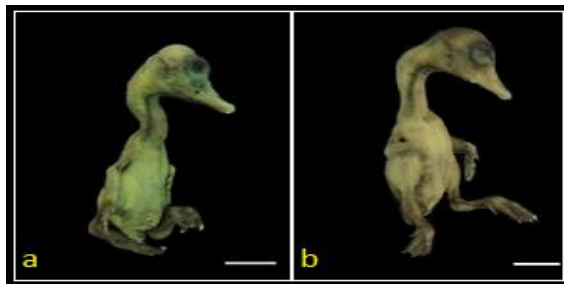


Figure 21. Photograph of 18 day old duck embryos treated with mixed nicotine and 50µg/ml *Syzygium cumini* using aqueous. Both have twitched neck, (a) has flat eyes (b) has white colored body. Scale bar = 15mm

Table 4. Percentage of Abnormalities Found on Treated 3-Day Old Duck Embryo After 15 Day Incubation

Part	Abnormalities	No. of Samples	Treatments								
			Negative Control		Positive Control						
			NT	PBS	NIC	AN1	AN2	AN3	BN1	BN2	BN3
Head	Microcephaly	15	0	0	14	2	3	0	3	3	1
	Open beak	15	0	0	5	1	1	0	0	1	0
	Unnatural head orientation	15	0	0	10	8	9	4	0	11	3
Eyes	Flat eyes	15	0	0	15	4	2	2	5	2	4
	No eyelids	15	0	0	4	2	0	0	2	1	0
	Eye absent	15	0	0	1	0	0	0	1	0	0
Beak	Curve beak	15	0	0	12	2	2	0	2	1	0
	Short beak	15	0	0	14	6	4	3	7	3	4
	Twisted	15	0	0	8	8	8	8	7	8	9
Neck	Neck longer than normal	15	0	0	7	0	0	0	0	0	0
	Neck shorter than normal	15	0	0	14	10	6	6	8	11	8
	Unproportioned	15	0	0	15	3	4	1	3	5	0
Body	Exposed organ	15	0	0	11	0	0	0	0	0	0
	White colored	15	0	0	4	3	0	0	2	1	1
	Swollen body	15	0	0	3	3	2	2	3	2	2
Wing	Wing absent	15	0	0	3	0	0	0	1	0	0
	Short wing	15	0	0	10	2	3	0	5	3	2
	Malformed	15	0	0	7	4	2	1	3	2	1
Leg	Leg absent	15	0	0	4	0	0	0	0	0	0
	Short leg	15	0	0	14	8	7	6	9	7	8
	Malformed	15	0	0	6	2	0	0	2	0	1
Others	Blood clot	15	0	0	8	4	2	2	5	3	3
	Weight loss	15	0	0	15	2	3	0	4	5	0
Percentage of Abnormalities = No. of abnormalities occurred in a group / total no. of abnormalities present x 100			0	0	100%	78%	65%	44%	83%	74%	57%

(Positive Control) NIC = 100µl of 0.001% Nicotine;

(Negative Control) NT = no treatment; PBS = contain 0.2ml Phosphate-Buffered Solution

Syzygium cumini Extract with 100µl of 0.001% Nicotine

AN1 = 0.2ml of 25µg/ml *Syzygium cumini* extract using, 70% ETOH

BN1 = 0.2ml of 25µg/ml *Syzygium cumini* extract using aqueous

AN2 = 0.2 ml of 50µg/ml *Syzygium cumini* extract using, 70% ETOH

BN2 = 0.2ml of 50µg/ml *Syzygium cumini* extract using aqueous

AN3 = 0.2ml of 100µg/ml *Syzygium cumini* extract using, 70% ETOH

BN3 = 0.2ml of 100µg/ml *Syzygium cumini* extract using aqueous

Malformations and abnormalities in embryo were induced by the teratogen nicotine. Nicotine has long been known to have teratogenic effects on embryos, but as research progressed more and more detrimental consequences to fetal development continued to be discovered. Use of products containing nicotine during pregnancy greatly increased the chances of miscarriage, impede lung and brain development, alter signaling pathways and paracrine factor levels in the fetal environment, produce problems with placental attachment and blood flow, and are associated with low birth weight babies, premature births, cleft palates, Sudden Infant Death Syndrome (SIDS), increased cancer risk, cognitive impairments and behavioral disorders (Maritz & Harding, 2011; Wickström, 2007).

Study by Joschko *et al.* (1991) in rat embryos confirmed that nicotine leads to growth retardation, and, in addition, demonstrated that development of the nervous system, particularly the forebrain, as well as the branchial arches was impaired, possibly leading to microcephaly and cleft palate respectively in term fetuses. Research in rats indicates that exposure of the fetus to nicotine during pregnancy results in delayed and abnormal brain development and behavioral disturbances in the newborn which may extend into adolescence (Slotkin *et al.*, 2006).

Nicotine could reduce oxygen and nutrient availability to the fetus by reducing placental blood flow, and could directly affect neuronal and other cell development. Children of smokers have an increased risk of Sudden Infant Death and this could be contributed to by nicotine exposure in utero. Furthermore,

one animal study showed that the offspring of rats exposed to nicotine prenatally were unable to mount an appropriate cardiorespiratory response to a hypoxic challenge, linking nicotine administration in the animal model to SIDS (Slotkin *et al.*, 1995). Suggested mechanisms for nicotine action include the possibility that the highly lipid soluble teratogen may exert its effects directly on the membranes or indirectly through oxidative membrane damage (Joschko *et al.*, 1991). Cellular disruption and necrosis occurred in the neuroepithelium and underlying mesenchyme, with the effect being dose dependent. Ultrastructurally, there was severe disruption of cell and organelle membranes, with many healthy cells containing engulfed, whole condensed or remnants of dead cells. Research demonstrates that nicotine acts as a nervous system teratogen leading to gross and cellular dysmorphology.

In terms of the percent of abnormalities that occurred in each treatment, it can be depicted that the highest percentage of abnormality was seen in NIC group which garnered 100%. Second is the BN1 group having 83% abnormalities, followed by the AN1 group having 78%. The BN2 group have 74% and the AN2 group have 65% abnormalities observed. Lesser abnormalities were observed in BN3 having 57% while the least of abnormalities were observed in the AN3 group having 44%. The antiteratogenic potential seemed more effective in the highest concentration of 100µg/ml in both ethanolic and aqueous extract of *Syzygium cumini*, than in the lower concentration of 25µg/ml. Those treated with AN1 and BN1 have the highest percentage of abnormalities observed which may imply that low concentrations of the extract is not sufficient to counteract the teratogenic activity of nicotine.

Antioxidant agents like tannins, flavonoids, phenols, polyphenols, and nitric acid, scavengers of free radicals such as peroxidase, hydrogen peroxidase or lipid peroxy thus inhibits the oxidative mechanism that lead to degenerative diseases.

Syzygium cumini are reported to be rich in flavonoids, a well-known antioxidant, which accounts for the scavenging of free radicals and protective effect on antioxidant enzymes (Ravi *et al.*, 2004) and also found to have high total phenolics with significant antioxidant activity (Bajpai *et al.*, 2005) and are fairly rich in protein and calcium. Antioxidants are believed to neutralize the free radicals in lipid chains by contributing a hydrogen atom usually from a phenolic hydroxyl group, which in turn converts phenolic groups into stable free radicals that do not initiate or propagate further oxidation of lipids (Shalaby *et al.*, 2010). The presence of anti-oxidants in the duhat extract confers protection to the duck embryo during development.

Java plums are rich in sugar, mineral salts, vitamins C. Vitamin C as an antiteratogen can decrease fetal malformation rate, diminish oxygen radical-related tissue damage, and ameliorate oxidative protein carbonylation in fetal livers as well as they can fully restore diabetes-induced lipid peroxidation and improve gestational outcome of a pregnant female Wistar rats (Assayed *et al.* 2010). Phytochemicals such as saponins, terpenoids, flavonoids, tannins, steroids and alkaloids have antiinflammatory effects. Glycosides, flavaloids, tannins and alkaloids have hypoglycemic activities (Lekha *et al.*, 2013). The above mentioned antioxidants present in the duhat pulp might be responsible for the antiteratogenic activity of *Syzygium cumini*.

SUMMARY, CONCLUSIONS AND RECOMMENDATIONS

A significant portion of congenital malformations in newborn infants is caused by teratogenic exposure. In order to prevent them, it is necessary to find substances that can counteract the effects of teratogen. In response, the study aimed to know the potential antiteratogenic property of *Syzygium cumini* to

nicotine, subjected to a three-day old duck (*Anas platyrhynchos*) embryo.

The duhat flesh is extracted individually using 70% ETOH and aqueous solution. Duck embryo assay was used and different treatments were administered to the embryos. The 15 treatments were namely: for the negative control were NT (no treatment) and PBS (phosphate buffer saline solution); for the positive control was NIC (nicotine); for the treated groups were A1, A2, A3, B1, B2, B3, AN1, AN2, AN3, BN1, BN2, and BN3. After two weeks of incubation, all the duck embryos were observed and gross morphological examination was done using morphometric analysis of the head length, eye diameter, culmen length, neck length, body length, total body length, wing length, leg length, and body mass.

Results shows that treated embryos with mixed nicotine and duhat crude extract have fewer abnormalities compared to the positive control group wherein nicotine only was administered. Statistical analysis of the shows that the potential antiteratogenic potential of duhat extract seems more effective in 100µg/ml in both ethanolic and aqueous extract. This implies that lower dosage of the extract is not sufficient in altering the teratogenic effects of nicotine in the embryos.

Descriptive data showed the occurrence of abnormalities found in each treatment. The embryos exhibited deformities in the head such as microcephaly, exposed brain, and unnatural head orientation. Flat eyes, absence of eyelids were also observed in the embryos while some exhibited an absence of eye. Malformations in the beak were observed to be curved and short. Twitched and short neck were observed in treated duck embryos while some exhibited a longer than normal neck. Malformation in the wings and legs were also observed in the embryos. Other treated embryos were observed to have unproportioned body, white colored and swollen body, and some

has exposed visceral organs. Blood clot was mostly observed in the head region of the embryos.

In comparing the percent of abnormalities that occurred in each treatment, it can be depicted that the highest percentage of abnormality was seen in NIC group which garnered 100%. Second is the BN1 group having 83% abnormalities, followed by the AN1 group having 78%. The BN2 group have 74% and the AN2 group have 65% abnormalities observed. Lesser abnormalities were observed in BN3 having 57% while the least of abnormalities were observed in the AN3 group having 44%.

Possible chemical components of the ethanolic and aqueous *Syzygium cumini* extract which may have antiteratogenic activity are antioxidant agents like tannins, flavonoids, phenols, polyphenols, and nitric acid, scavengers of free radicals such as peroxidase, hydrogen peroxidase or lipid peroxy thus inhibits the oxidative mechanism that lead to degenerative diseases. Phytochemicals such as saponins, terpenoids, flavonoids, tannins, steroids and alkaloids have anti-inflammatory effects .Glycosides, flavonoids, tannins and alkaloids have hypoglycemic activities. Vitamin C that is considered as antiteratogen can decrease fetal malformation rate, diminish oxygen radical-related tissue damage.

Based on the obtained results, the following were concluded:

1. Both aqueous and ethanolic extracts of the fruit of *Syzygium cumini* were rich in saponins, tannins, reducing sugar, glycosides, alkaloids, flavonoids, terpenoids and phenols.
2. Duhat crude extract, extracted using 70% ETOH has higher yield of altering malformations caused by nicotine compared to duhat crude extract, extracted using aqueous solution.
 - Among the two duhat crude extracts tested, the dosage that seemed more effective was 100µg/ml.

3. Duhat crude extracts have lessened the malformations induced by the teratogenic nicotine on the duck embryo's head length, culmen length, neck length, wing length, leg length, body length, total body length, and body mass.
 - Moreover, as the concentration of the duhat crude extract that is administered in the duck embryos increased, it lessened the abnormalities induced by nicotine.
4. 25, 50, and 100µg/ml of both *Syzygium cumini* extract using 70% ETOH and aqueous solution are not teratogenic

Upon conducting the study, the following were recommended:

1. Other morphological parameters may be considered in assessing the antiteratogenic activity of duhat crude extract.
2. Researchers must conduct histological analysis to reinforce the finding of the antiteratogenic potential of duhat crude extract.
3. Other test organisms may be used in the biological assay in order to further assess the effectivity of the antiteratogenic potential of the duhat extract.

The antiteratogenic potential of duhat extract may also be tested in other known teratogens.

LITERATURE CITED

1. Abletis, A.M., 2011. *Determination of Anti-teratogenic potential of Garcinia mangostana Linn. Extract on the gross morphology of the developing duck Anas platyrhynchos.*
2. Adelia, F., C. Marcella and Z. Mercadante. 2011. *Identification of bioactive compounds from Jambolao (Syzygium cumini) and antioxidant capacity evaluation in different pH conditions.* Food Chemistry. 126(4):1571-1578.
3. Ahmad, K., T. Nauroze, A. Kausar, B. Raees, T. Abbass, A. Muhammad, A. Kanwal and S. Jabeena. 2012. *Protective role of Jambul fruit pulp extract against fluoride induced toxicity in mice.* Research Report Fluoride. 45(3):281-289.
4. Aiyelaagbe, O.O. and P.M. Osamudiamen. 2009. *Phytochemical Screening for Active Compounds in Mangifera indica Leaves from Ibadan, Oyo State.* Plant Sciences Research. 2(1):11-13.
5. Andersson, C., P. Wennstrom and J. Gry. 2003. *Nicotine alkaloids in Solanaceous food plants.* Tema Nord. 531:1-37.
6. Assayed, M.E., A.A. Khalaf and H.A. Salem. 2010. *Protective effects of garlic extract and vitamin C against in vivo cypermethrin-induced teratogenic effects in rat offspring.* Food and Chemical Toxicology. 48:3153-3158.
7. Ayyanar, M., and P. Subash-Babu. 2012. *Syzygium cumini (L.) Skeels: A review of its phytochemical constituents and traditional uses.* Asian Pac J Trop Biomed. 2(3):240-246.
8. Bajpai M., A. Pande, S.K. Tewari and D. Prakash. 2005. *Phenolic contents and antioxidant activity of some food and medicinal plants.* Int J Food Sci Nutr. 56:287-291.
9. Banjeree, A., N. Dasgupta and B. De. 2005. *In vitro study of antioxidant activity of Syzygium cumini fruit.* Food Chemistry. 90(4): 727-733.
10. Bimakr, M., R.A. Rahmana, F.S. Taipa, A. Ganjloob, L.M. Salleha, J. Selamat, A. Hamidc and I. Zaidul. 2011. *Comparison of different extraction methods for the extraction of major bioactive flavonoid compounds from spearmint (Mentha spicata L.) leaves.* Food and Bioproducts Processing. 89:67-72.

11. Boulland, J., G. Halasi, N. Kasumacic and J. Glover. 2010. *Xenotransplantation of human stem cells into the chick embryo*. J Vis Exp. 41: 2071.
12. Buchanan, R., 1994. *A Short History of Tobacco: The Most Provocative Herb*. The Herb Companion. 34-38.
13. Ceballos, P., J. Molina and B. Palacios. 1989. *Manual Del Anillador*. Icona-Mapa. 94-113.
14. Centers for Disease Control and Prevention, 2013. The emergency response safety and health database. Retrieved from: http://www.cdc.gov/niosh/erashdb/emergencyresponsecard_29750028.html
15. Centers for Disease Control and Prevention, 2013. National Biomonitoring Program. Retrieved from: http://www.cdc.gov/biomonitoring/Cotinine_BiomonitoringSummary.html
16. Centers for Disease Control and Prevention, 2014. Reproductive Health. Retrieved from: <http://www.cdc.gov/reproductivehealth/TobaccoUsePregnancy/>
17. Chandrakar, M., F. Dar and S. Chandrakar. 2011. *Response of chick embryo to the nicotine induction*. Asian J. Exp. Biol. Sci. 2(1):34-39.
18. Chaudhary, B. and K. Mukhopadhyay. 2012. *Syzygium cumini (L.) Skeels: A Potential source of nutraceuticals*. International Journal of Pharmacy and Biological Sciences. 2(1):46-53.
19. Chung, K., T. Wong, C. Wei, Y. Huang and Y. Lin. 1998. *Tannins and human health: A review*. Crit Rev Food Sci Nutr. 38(6):421-464.
20. Dalgic, A., E. Armagan and F. Helvacioğlu. 2009. *High Dose Cotinine may induce neural tube defects in chick embryo*. Turkish Neurosurgery. 19 (3):224-229.
21. Domino, E., E. Hornbach and T. Demana. 1993. *The Nicotine Content of Common Vegetables*. N Engl J Med. 329-437.
22. Elewa, A., 2004. *Morphometrics*. Earth System Science. p 265
23. England, L., J. Kendrick, H. Wilson, R. Merritt, R. Garguillo and C. Zahniser. 2001. *Effects of smoking reduction during pregnancy on the birth weight of term infants*. Am. J. Epidemiol. 154(8):694-701.

24. Erickson, A.C. and L.T. Arbour. 2012. *Heavy smoking during pregnancy as a marker for other risk factors of adverse birth outcomes: A population-based study in British Columbia, Canada*. BMC Public Health.12:102.
25. Ernst, M., E.T. Moolchan and M.L. Robinson. 2001. *Behavioral and neural consequences of prenatal exposure to nicotine*. J Am Acad Child Adolesc Psychiatry. 40(6):630-641.
26. FAO Corporate Document Repository, 2014. Retrieved from: <http://www.fao.org/docrep/005/ac802e/ac802e08.htm>
27. Francesch, A. and M. Cartana. 2011. *Morphology for morphological characterization of chicken and its application to compare Penedesenca and Empordanesa breeds*. Animal Genetic Resources. 48:79-84.
28. Global Invasive Species Database, 2006. Retrieved from: <http://www.issg.org/database/species/ecology.asp?si=505>
29. Gordon, A. and E. Jungfer. 2011. *Phenolic Constituents and Antioxidant Capacity of Four Underutilized Fruits from the Amazon Region*. Journal of Agricultural and Food Chemistry. 59:7688-7699.
30. Gueye, E. F., 1998. *Village egg and fowl meat production in Africa*. World Poultry Sci. 54:73-86.
31. Hegazy, A.E. and M.I. Ibrahim. 2012. *Antioxidant Activities of Orange Peel Extract*. World Applied Sciences Journal. 18(5):684-688.
32. Heiser, C.B., 1992. *On Possible Sources of Tobacco in Eastern North America*. Americal Antiquity. 49:269-287.
33. Hossain, A., and S. Salehuddin. 2013. *Analytical Determination of Nicotine in Tobacco Leaves by Gas Chromatography-Mass Spectrometry*. Arabian Journal of Chemistry. 6 (3):275-278.
34. Inaloz, H.S., S.S. Inaloz, E. Deveci and A. Eralp. 2000. *Teratogenic effects of nicotine in rat skin*. Clin Exp Obstet Gynecol. 27(3-4):241-243.
35. Johnson, I.T., J.M. Gee, K. Price, C. Curl and J. Takahashi. 2006. *Effects of saponins on gut permeability and active nutrient transport in vitro*. J. Anim. Nutri. 116: 2270-2277.
36. Joschko, M.A., I.E. Dreosti and R.S. Tulsi. 1991. *The teratogenic effects of nicotine in vitro in rats: a light and electron microscope study*. Neurotoxicol Teratol.13(3):307-16.

37. Kallen, K., 1998. *Maternal Smoking, Body Mass Index and Neural Tube Defects*. Am. J. Epidemiol. 147(12):1103-1111.
38. Kiritkar, K.R. and B.D. Basu. 1995. *Indian medicinal plants*. Periodical Experts. 11:1052-1053.
39. Khaldoyanidi, S., L. Sikora, I. Orlovskaya, V. Matrosova, V. Kozlov and P. Sriramarao. 2001. *Correlation between nicotine-induced inhibition of hematopoiesis and decreased CD44 expression on bone marrow stromal cells*. Blood: 98 (2).
40. Kubola, J., S. Siriamornpun and N. Meeso. 2011. *Phytochemicals, Vitamin C and Sugar Content of Thai Wild Fruits*. Food Chemistry .126(3):972-981
41. Laghari, A.Q., S. Memon, A. Nelofar and H.F. Laghari. 2011. *Extraction, Identification and Antioxidative Properties of the Flavonoid-Rich Fractions from Leaves and Flowers of Cassia angustifolia*. American Journal of Analytical Chemistry. 2:871-878.
42. Landoni, J.H., 1990. *Nicotiana tabacum* L. Retrieved from: <http://www.inchem.org/documents/pims/plant/nicotab.htm#SectionTitle:3.1> Description of the plant
43. Lekha, K.N., B. Maleeka and S. Geetha. 2013. *In vitro-Antioxidant activity of the seed and leaf extracts of Syzygium cumini*. IOSR Journal of Environmental Science, Toxicology and Food Technology. 2319-2402.
44. Leyden, D., E. Leitner and B. Seigmund. 1999. *Determination of Nicotine in Pharmaceutical Products and Dietary Sources*. Elsevier Science BV. 393-395.
45. Mahato, S.B. and S. Sen. 1997. *Advances in triterpenoid research*. Phytochemistry. 44: 1185-236.
46. Maritz, G. and R. Harding. 2011. *Life-long programming implications of exposure to tobacco smoking and nicotine before and soon after birth: Evidence for altered lung development*. International Journal of Environmental Research and Public Health. 8:975-898.
47. Memon, S., and M. Pratten. 2013. *Teratogenic Effects of two known teratogens (Nicotine and Cadmium) and Prevention of such Effects by Addition of Antioxidant in Chick Embryos: An Evaluation of Two Culture Systems (Micromass and Inovo Culture)*. IOSR-JDMS. 7(5):27-38.

48. Merck Index, 1996. The Merck Index. An encyclopedia of Chemicals, Drugs, and Biologicals. 12th Edition. S. Budavari, M.J. O'Neil, A. Smith, P.E. Heckelman, and J.F. Kinneary (Eds.), Merck & Co. Inc., Whitehouse Station.
49. Miller, R.R., C.D. Heckel, W.J. Koss, S.L. Montague and A.L. Greenman. 2001. *Ethanol and nicotine-induced membrane changes in embryonic and neonatal chick brains*. PubMed. 130(2):163-78.
50. Modi, D.C., J.K. Patel, B.N. Shah and B.S. Nayak. 2010. *Pharmacognostic Studies of the Seed of *Syzygium cumini* Linn.* International Journey of Pharmaceutical Sciences. 1(1):20-26.
51. Morton, J., 1987. Fruits of warm climates. Retrieved from: http://www.ctahr.hawaii.edu/sustainag/extn_pub/fruitpubs/Mountain%20Apple.pdf.
52. Nwoke, M.B., 2008. The effects of teratogen on the health of developing human beings. Retrieved from: http://www.crisanet.org/docs/conference_08/Papers/CAUSES_COSEQUENCES_DRUG_USE/Nwoke_Teratogens.pdf
53. Ojedapo, L.O., S.R. Amao, S.A. Ameen, T.A. Adediji, R.I. Ogundipe and A.O. Ige. 2012. *Prediction of Body Weight and other Linear Body Measurement of Two Commercial Layer Starin Chickens*. Asian Journal of Animal Sciences. 1-10.
54. Oster, G., T.E. Delea and G.A. Colditz. 1988. *Maternal smoking during pregnancy and expenditures on neonatal health care*. Am J Prev Med. 4(4):216-219.
55. Pandey, K.B., and S.I. Rizvi. 2009. *Plant polyphenols as dietary antioxidant in human health and disease*. Oxid Med Cell Longev. 2(5):270-278.
56. Pictet, A. and P. Crepieux. 1895. *Uber phenyl-und pyridylpyrrole und die konstitution des nicotins*. Ber. 28:1904–1910.
57. Pietta, P.G., 2000. *Flavonoids as Antioxidant*. J Nat Prod. 63(7):1035-1042.
58. Price, K., I. Johnson, J. Gee, C. Curl and R. Fenwick. 1986. *Influence of saponins on gut permeability and active nutrient transport in vitro*. The Journal of Nutrition. 116:2270-2277.
59. Purdue University, Center for New Crops and Plant Products, 2014. Retrieved from: <http://www.hort.purdue.edu/newcrop/morton/jambolan.html>

60. Ravi K., B. Ramachandran and S. Subramanian. 2004. *Protective effect of Eugenia jambolana seed kernel on tissue antioxidants in streptozotocin induced diabetic rats*. Biol Pharm Bull. 27:1212–1217.
61. Reynertson, K.A., M.J. Basile and E.J. Kennelly. 2005. *Antioxidant potential of seven myrtaceous fruits*. Ethnobot Res Appl. 3:25–35.
62. Rekha, N., R. Balaji and M. Deecaraman. 2010. *Antihyperglycemic and antihyperlipidemic effects of extracts of the pulp of Syzygium cumini and bark of Cinnamon zeylanicum in streptozotocin-induced diabetic rats*. Journal of Applied Bioscience. 28:1718-1730.
63. Roja, G. and M.R. Heble. 1994. *The quinoline alkaloid camptothecin and 9-methoxy camptothecin from tissue cultures and mature trees of Nothapodytes foetida*. Phytochemistry. 36:65–6.
64. Sah, A. and V. Verma. 2011. *Syzygium cumini: An Overview*. J Chem. Pharm. Res. 3(3):108-113.
65. Sambrook, J., E.F. Fritsch and T. Maniatis. 1989. *Molecular Cloning: A Laboratory Manual*, 2nd Edn. Cold Spring Harbor Laboratory Press, Cold Spring Harbor, NY. Vol.3, App B.12.
66. Saxena, M., J. Saxena, R. Nema, D. Singh and A. Guota. 2013. *Journal of Pharmacology and Phytochemistry*. Journal of Pharmacognosy and Phytochemistry. 1(6):168-182.
67. Sayers, N.M., D.B. Drucker, D.R. Telford and J.A. Morris. 2014. *Effects of nicotine on bacterial toxins associated with cot death*. Archives of Disease in Childhood. 73:549-551.
68. Schevelbein, H. 1982. *Nicotine Resorption and Fate*. Pharm. Therm. 18:233-248.
69. Schevelbein, H., 1962. *Nicotine Rauchen und organismus-Beitr*. Tabakforsch. 199–274.
70. Seigfried, J. and J. Rende. 2010. *The long term effects of prenatal nicotine exposure on neurologic development*. J Midwifery Womens Health. 55(2):143-152
71. Shalaby, E.A., S.M. Shanab and V. Singh. 2010. *Salt stress enhancement of antioxidant and antiviral efficiency of Spirulina platensis*. J. Med. Plants Res. 4(24): 2622-2632.

72. Sharma, A., V. Patel and A. Chaturvedi. 2009. *Vibriocidal activity of certain medicinal plants used in Indian folklore medicine by tribals of Mahakoshal region of central India*. Indian Journal of Phramacology. 41:129-133.
73. Singh, A.M. and W.W. Busse. 2006. *Asthma exacerbations: Aetiology*. Thorax. 61(9):809-816.
74. Slotkin, T.A., C.A. Tate, M.M. Cousins and F.J. Seidler. 2006. *Prenatal nicotine exposure alters the responses to subsequent nicotine administration and withdrawal in adolescence: Serotonin receptors and cell signaling*. Neuropsychopharmacology. 31: 2462-2475.
75. Slotkin, T.A., S.E. Lappi, E.C. McCook, B.A. Lorber and F.J. Seidler. 1995. *Loss of neonatal hypoxia tolerance after prenatal nicotine exposure: implications for sudden infant death syndrome*. Brain Research Bull. 38: 69-75.
76. Solomon, F.V., 1996. *Allgemeines Bauprinzip und äußere Anatomie der Vögel. Lehrbuch der Geflügelanatomie (Hrsg. F-V. Solomon)*. Jena: Gustav. Fischer Verlag. 19-25.
77. Southeast Asia Tobacco Control Research, 2007. *Protecting the Right to Life: Smoke Free Public Places in Asean*. Retrieved from: www.globalsmokefree.com/gsp/ficheiro/127.doc
78. Swami, S., N. Thakor, M. Patil and P. Haldankar. 2012. *Jamun: A review of its food and medicinal uses*. Food and Nutrition Sciences. 3:1100-1117.
79. Talukdar A.D., M.D. Choudhary, M. Chakraborty and B.K. Dutta. 2010. *Phytochemical screening and TLC profiling of plant extracts *Cyatheagigantea* (Wall. Ex. Hook.) Haltt. and *Cyatheabrunoniana*. Wall. ex. Hook.* Assam University Journal of Science & Technology: Biological and Environmental Science. 5(1):70-74.
80. Tanwar, R., S. Sharma, U. Singh and K. Prahbu. 2011. *Antiatherosclerotic Potential of Active Principle Isolated from *Eugenia jambolana* in Streptozotocin-Induced Diabetic Rats*. Evidence-Based Complementary and Alternative Medicine. 2011:1-9.
81. Tariq, A.L. and A.L. Reyaz. 2013. *Phytochemical Analysis of *Camellia sinensis* Leaves*. IJDDR. 4(4):311-316.

82. Tobacco Atlas, 2009. Promoting, Smoke free individuals. Retrieved from: <http://www.wpro.who.int/philippines/publications/module5.pdf>
83. Vlase, L., L. Filip, L. Mindrutau and S. Leucuta. 2005. *Determination of Nicotine from Tobacco by LC-MS-MS*. Studia Universitatis Babes-Bolyai, Physica, L. 4b:19-24.
84. Warin, S., 2006. *Embryonic Development*. Ceva Animal Health Asia Pacific. Issue No. 6.
85. Wickström, R.R., 2007. *Effects of nicotine during pregnancy: Human and experimental evidence*. Neuropharmacology. 5(3):213-222.
86. Wisborg, K., U. Kesmodel, T.B. Henriksen, S.F. Olsen and N.J. Secher. 2000. *Exposure to Tobacco Smoke in Utero and the Risk of Stillbirth and Death in the First Year of Life*. Am. J. Epidemiol.154 (4):322-327.
87. Zhou, Z., Z. Del Prosto, L. Wu, J. Xu, J. Hua, Y. Zhou, Y. Ye, Z. Zhang, J. Hu and E. Haacke. 2012. *In ovo serial skeletal muscle diffusion tractography of the developing chick embryo using DTI: feasibility and correlation with histology*. BMC Developmental Biology. 12:38.