

## A study of effect on visual acuity and contrast sensitivity following Nd-YAG laser capsulotomy in patients with posterior capsular opacification

ISHTIYAQ JASIYA

BHAT PARVEZ AHMAD

Senior Resident Ophthalmology  
SKIMS, Soura, Srinagar (J&K), India

ANAND OM PRAKASH

Head of department ophthalmology  
NRCH, New Delhi, India

QADRI SYED SHUJA<sup>1</sup>

Senior Resident, Department of Community Medicine  
SKIMS, Soura, Srinagar (J&K), India

GAGNEJA NEETU

Senior Resident, Ophthalmology  
NRCH, New-Delhi, India

ARSALAN-UN-NISA

Post graduate, Ophthalmology, GMC Srinagar, India

### Abstract:

**Objective:** To study the effect of Nd-YAG capsulotomy on visual acuity and contrast sensitivity in patients with posterior capsular opacification following cataract surgery. **Material and methods:** A total of 100 eyes (87 patients) were enrolled for the study who went Nd-YAG laser capsulotomy. Patients who had undergone uncomplicated phacoemulsification cataract surgery with implantation of foldable intraocular lens were included and patients with associated ocular diseases were excluded. Visual acuity and contrast sensitivity were measured with snellen acuity chart and pelli-Robson chart respectively at day 1, day 7, 1 month and 3 months following procedure. **Results:** Pre-laser visual acuity was compared with Day1 visual acuity and it showed that the improvement in visual

*acuity on Day1 was found to be statistically significant (p value= .001) indicating an immediate improvement in visual acuity after this procedure. Visual acuity done on D7 of capsulotomy showed that the improvement of visual acuity was also found to be statistically significant (p value=.000). Visual acuity done at 1 month of capsulotomy showed the improvement of visual acuity when compared to pre-laser values was found to be statistically significant (p value=.000). Visual acuity done at 3 months of capsulotomy remained same as at 1 month. This improvement when compared to pre-laser visual acuity was found to be statistically significant (p value=.0.000). Mean value of pre-laser contrast sensitivity was compared with contrast sensitivity at D1, D7, 1month and 3months. Pre-laser mean value of contrast sensitivity was 1.1538 which was compared with mean value during follow up (mean value 1.5235). The improvement in contrast sensitivity was found to be statistically significant (p value=0.000). **Conclusion:** Nd-YAG capsulotomy definitely improves both visual acuity and contrast sensitivity in patients with significant PCO and maximum improvement occurs within first month following Nd-YAG capsulotomy.*

**Key words:** Nd-YAG-neodenum yettrium almunium garnite, Posterior capsular opacification

## **Introduction**

Posterior capsular opacification (PCO) is the most common late post-operative complication of cataract surgery occurring in up to one-third of patients in a period of five years.<sup>1</sup> PCO is a major problem in pediatric cataract surgery where the incidence approaches 100%.<sup>2</sup> One of the crowning achievements of modern cataract surgery has been a gradual, almost unnoticed decrease in the incidence of this complication due to operative steps like hydrodissection enhanced cortical clean-up, posterior capsular polishing, performance of capsulorrhexis slightly

---

<sup>1</sup> Corresponding author: ssaqadri@yahoo.com

smaller than the diameter of the IOL optic and in-the-bag implantation of IOL.<sup>3</sup> Several IOL related factors have also been studied for prevention of PCO which includes use of a biocompatible IOL to reduce stimulation of cellular proliferation, enhancement of contact between the IOL optic and posterior capsule and use of an IOL with a square, truncated optic edge. The visual symptoms produced by the PCO may mimic those of the primary cataract. Thus, PCO is often referred to as a “secondary cataract.” Patients generally notice a slow decline in visual quality after the initial visual improvement following cataract surgery. Interval between surgery and PCO varies widely ranging from three months to four years after the surgery. PCO formation is an attempt by the eye to make a new lens from remaining lens material. The two morphologically distinct types of PCO are fibrosis and Elschnig’s pearls which occur independently or in combination. In addition ECCE procedures may result in formation of Soemmering’s ring. Visual symptoms do not always correlate to the observed amount of PCO. Some patients with significant PCO on slit lamp examination are relatively asymptomatic while others have significant symptoms with mild apparent haze, which is reversed by capsulotomy<sup>4</sup>. The current treatment of choice is Neodymium:Yttrium-Aluminum-Garnet (Nd:YAG) laser capsulotomy. It gives instantaneous results and can easily be administered in an out-patient setting. It is a noninvasive procedure that has completely replaced surgical capsulotomy. With this background the aims of the study was to study the changes in visual acuity, contrast sensitivity following Nd:YAG laser capsulotomy.

## **Material and methods**

This study was a prospective study was performed to evaluate the change in visual parameters including visual acuity and

contrast sensitivity associated with Nd: YAG laser capsulotomy. The study was reviewed by both the ethical and scientific committee of the institute and was granted approval. Target population consisted of patients who visited Ophthalmology department of NRCH, New Delhi, between May 2010 and October 2011, with significant visual impairment due to posterior capsule opacification. A total of 100 eyes (87 patients) were enrolled for the study who underwent Nd: YAG laser capsulotomy. Patients who had undergone uncomplicated phacoemulsification surgery with implantation of foldable intraocular lenses were included and patients with any other associated ocular disease were excluded in this study. Each patient was evaluated before undergoing laser capsulotomy to confirm that the visual loss was only due to PCO. Visual acuity was checked using Snellens visual acuity chart. Contrast sensitivity was assessed using Pelli Robson Chart at 1 m distance. Post laser visual acuity and contrast sensitivity was recorded on 1<sup>st</sup> day, 7<sup>th</sup> day, 1 month and 3 months of procedure. Analysis of the study data was done with Microsoft Excel XP Windows 2007 (Microsoft, Seattle WA) and SPSS version 13.0 (SPSS inc., Chicago, IL) software. Comparison of difference of means at two point of time were made with a paired t-test. The data was further analyzed using Chi-square test and Wilcoxon signed ranks test. A value of  $p < 0.05$  was considered statistically significant.

## **Results**

### **Changes in visual acuity**

Pre-laser visual acuity was compared with Day1 visual acuity and it showed that all the cases with VA 6/12 improved to VA 6/9. In patients with pre-laser VA 6/18, 73% cases gained visual acuity 6/9 on day 1; there was no improvement in one case. In patients with pre-laser VA 6/24, 63% improved to 6/9 or better.

In patients with VA 6/36, 75% cases gained 6/12 or better. In patients with VA 6/60, 60% gained 6/12, There was only 1 case with VA Finger Counting at 1m who improved to 6/18 on D1. The improvement in visual acuity on Day1 was found to be statistically significant (p value= .001) indicating an immediate improvement in visual acuity after this procedure. Visual acuity done on D7of capsulotomy showed that in VA 6/18 group, 90% cases gained 6/12or better. In VA 6/24 group, 84% had VA 6/9 or better. In VA 6/36 group, 50% had VA 6/9 or better. In VA 6/60 group, 90% had 6/12. There was only 1 case with VA FC at 1m who improved to 6/9 on D7. The improvement of visual acuity on day 7 was found to be statistically significant (p value=.000). Visual acuity done at 1 month of capsulotomy showed that in 6/18 group, 92 % gained 6/9 or better vision. In 6/24 group, 88% cases gained 6/9 or better vision. The improvement of visual acuity when compared to pre-laser values was found to be statistically significant (p value=.000). Visual acuity done at 3 months of capsulotomy remained same as at 1 month. This improvement when compared to pre-laser visual acuity was found to be statistically significant (p value=.000).

### **Change in contrast sensitivity:**

Mean value of pre-laser contrast sensitivity was compared with contrast sensitivity at D1, D7, 1month and 3months. Pre-laser mean value of contrast sensitivity was 1.1538 which was compared with mean value during follow up (mean value 1.5235). The improvement in contrast sensitivity was found to be statistically significant (p value=0.000).

### **Discussion**

The study consisted of 100 eyes (87 patients) of whom 61 (61%) were males and 39 (39%) females. The age of patients ranged

from 14 to 86 years with a mean of 63.42 years and median of 64.5 years. The incidence is directly linked to the incidence of cataract in this age group. Out of 100 cases in our study, 64% had Elschnig's pearls and 36% had fibrosis type of PCO. Javed EA<sup>50</sup> also found that Elschnig's pearl is the most common type. Saeed MK<sup>55</sup> found that 67% had pearls type and 33% had fibrosis type of PCO. In a study conducted by Dawood Z<sup>49</sup>, 56.07% patients presented with Elschnig's pearls, 42.33% had capsular fibrosis and 1.60% had capsular wrinkling.

The time interval between cataract surgery and capsulotomy ranged between 6 months to > 5 years with maximum cases between 1 and 3 years (61%) and 18% within 1 year. Khanzada MA<sup>54</sup> found that the mean time interval between cataract surgery and Nd:YAG laser posterior capsulotomy was 2-5 years. Burq MA<sup>51</sup> found that majority of patients (93.3%) who underwent laser capsulotomy presented within 3 years after cataract surgery. In our study we could not find correlation between age and onset of capsular opacification owing to highest number (65%) of cases in the age groups 50-70 yrs and only 8 % of cases in the age group < 50 years.

Improvement in visual acuity and contrast sensitivity are the main aims for successful YAG laser posterior capsulotomy. Previous reports have focused primarily on visual acuity improvement after Nd:YAG laser as the main outcome measure. But this is inadequate to assess visual function which necessitates evaluation of contrast sensitivity<sup>57</sup>. In our study, pre-laser visual acuity ranged from 6/12 to finger counting at 1 metre and 57% cases achieved visual acuity of 6/9 on D1 of capsulotomy and on D7, 62% cases had visual acuity of 6/9 and 14 % achieved visual acuity of 6/6. BCVA was given after 1 month and it was found that 56% cases gained visual acuity of 6/9, 22% had visual acuity of 6/6 and 19% had visual acuity of 6/12 after capsulotomy. The visual improvement in our study correlates with the findings of other studies. Hossain MI et al.<sup>32</sup>

found that 76% patients gained 6/12 or better vision after 7 days. According to a study conducted by Rasool W<sup>39</sup> only 7% patients had good best corrected visual acuity (6/18) prior to Nd:YAG laser capsulotomy and after one week of follow-up there was significant improvement in 73% patients. Wakamatsu<sup>38</sup> found that there was a significant improvement in the mean functional visual acuity, from  $0.18 \pm 0.11$  logMAR to  $0.08 \pm 0.07$  logMAR ( $P < .05$ ).

In our study, pre-laser mean value of contrast sensitivity was 1.1538 which was compared with mean value during follow up (mean value 1.5235). The improvement in contrast sensitivity was found to be statistically significant ( $p$  value=0.000). El Hatew<sup>33</sup> found that improvement of visual acuity ranged from 6/36 (11.84%) to 6/9 (5.9%) and improvement in contrast sensitivity ranged from  $41.2 \pm 53.3$  before laser treatment to  $110.2 \pm 76.9$  after laser treatment. In a study, conducted by Wang J et al.<sup>34</sup> visual acuity, contrast sensitivity curve and glare sensitivity curve improved in all cases postoperatively which was very significant. Mortazavi et al.<sup>36</sup> also studied the above parameters for visual function and they found that average visual acuity, contrast sensitivity and glare sensitivity before Nd:YAG laser capsulotomy was 20/37, 20/83 and 20/95 respectively that changed to 20/24, 20/50, and 20/64 after capsulotomy. Claesson M<sup>37</sup> studied the benefits of Nd:YAG laser capsulotomy on visual performance, following capsulotomy, and found that VA and contrast sensitivity both improved significantly.

## **Conclusion:**

Nd-YAG capsulotomy definitely improves both visual acuity and contrast sensitivity in patients with significant PCO and maximum improvement occurs within first month following Nd-YAG capsulotomy.

Ishtiyag Jasiya, Bhat Parvez Ahmad, Anand Om Prakash, Qadri Syed Shuja, Gagneja Neetu, Arsalan-un-nisa- **A study of effect on visual acuity and contrast sensitivity following Nd-YAG laser capsulotomy in patients with posterior capsular opacification**

**Tables:- (TABLE-1) PRE AND POST LASER VISUAL ACUITY**

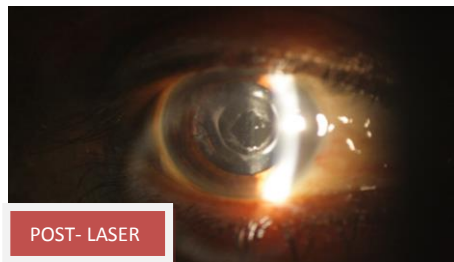
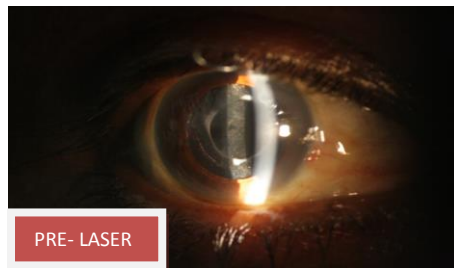(VA)-visual acuity, (D)-days,( M)-months

Pre laser VA	no. of pat	POST LASER VA																				
		6/6				6/9				6/12				6/18				6/24				
		D1	D7	1 M	3 M	D1	D7	1 M	3 M	D1	D7	1 M	3 M	D1	D7	1 M	3 M	D1	D7	1 M	3 M	
6/12	4	0	0	0	0	4	4	4	4	0	0	0	0	0	0	0	0	0	0	0	0	0
6/18	48	1	12	17	18	34	31	27	27	12	4	3	2	1	1	1	1	0	0	0	0	0
6/24	25	1	1	4	4	15	18	18	18	8	4	2	2	1	0	1	1	0	0	0	0	0
6/36	12	0	1	1	1	4	5	5	5	5	5	5	5	3	1	1	1	0	0	0	0	0
6/60	10	0	0	0	0	0	1	1	1	6	9	9	9	3	0	0	0	1	0	0	0	0
CF 1	1	0	0	0	0	0	1	1	1	0	0	0	0	0	0	0	0	0	0	0	0	0

**Table 2. Pre-Laser And Post-Laser Contrast Sensitivity**

	C.S. PRE LASER	C.S. D1	C.S. D7	C.S. 1 MONTH	C.S. 3 MONTHS
No.of eyes	100	100	100	100	100
Minimum	.60	1.20	1.20	1.20	1.20
Maximum	1.65	1.80	1.80	1.80	1.80
Range	1.05	.60	.60	.60	.60
Mean	1.1538	1.5235	1.5235	1.5220	1.5220
Std. Deviation	.22624	.13074	.13074	.13358	.13358
Median	1.2000	1.5000	1.5000	1.5000	1.5000
Std. Error of Mean	.02262	.01307	.01307	.01336	.01336

CS-contrast sensitivity, D-days





## **REFERENCES:**

1. Schaumberg DA, Dana MR, Christen WG, Glynn RJ. A systematic overview of the incidence of posterior capsule opacification. *Ophthalmology* 1998; 105: 1213-21.
2. Pandey SK, Wilson ME, Trivedi RH, Izak A, Macky TA, Werner L, et al. Pediatric cataract surgery and intraocular lens implantation: current techniques, complications and management. *Int Ophthalmol Clin.* 2001;41:175-96.
3. Apple DJ, Peng Q, Visessook N, Werner L, Pandey SK, Escobar-Gomez M, et al. Eradication of posterior capsule opacification. *Ophthalmology* 2001;108:505-18.
4. Cheng CY, Yen MY, Chen SJ, Kao SC, Hsu WM, Liu JH. Visual acuity and contrast sensitivity in different types of posterior capsule opacification. *J Cataract Refract Surg.* 2001;27:1055-60.
5. Javed EA, Ahmed ZD, Sultan M. Nd:YAG capsulotomy and complications. *Professional Med J.* Dec 2007;14(4):616-619.
6. Saeed MK, Ameen SS, Ibrahim MT, Ijaz U, Hanif K. Raised Intraocular Pressure; Frequency after Nd: YAG laser capsulotomy. *Professional Med J.* Sep 2009;16(3):410-413.
7. Dawood Z, Mirza SA, Qadeer A. Review Of 560 Cases Of YAG Laser Capsulotomy JIumhs. 2007;6(1):3-1.
8. Khanzada MA, Jatoi SM, Narsani AK, Dabir SA, Gul S. Is Nd: YAG Laser a Safe Procedure for Posterior Capsulotomy? *Pak J Ophthalmol.* 2008; 24( 2):73-78.
9. Burq MA, Taqui MA. Frequency of Retinal Detachment and Other Complications after Neodymium: YAG Laser Capsulotomy. *J Pak Med Assoc.* 2008 oct;58(10):550-2.
10. Lasa MS, Datiles MB , Podgor MJ, Magno BV. Contrast and glare sensitivity association with the type and severity of the cataract. *Ophthalmology.* 1992;99(7):1045-1049.

11. Hossain MI, Hossain MA, Hossain MJ. Visual outcome after Nd: YAG laser capsulotomy. JAFMC Bangladesh. 2009;5(2):29-31.
12. Rasool W, Raza A, Ali SA. Efficacy of Laser Capsulotomy in the Treatment of Posterior Capsule Opacification. Journal of Rawalpindi Medical College (JRMC). 2010;14(2):78-80.
13. Wakamatsu TH, Yamaguchi T, Negishi K, Kaido M, Matsumoto Y, Ishida R, Kojima T, Ibrahim OM, Saiki M, Dogru M, Tsubota K. Functional visual acuity after Neodymium:YAG laser capsulotomy in patients with posterior capsule opacification and good visual acuity preoperatively. J Cataract Refract Surg. 2011 Feb;37(2):258-64.
14. El Hatew MHAE, Osama MK, Mostafa AH. Evaluation of changes in visual acuity and contrast sensitivity after Nd: YAG laser posterior capsulotomy. Bull Ophthalmol.Soc.Egypt 1998;91(2):381-383.
15. Wang J, Sun B, Yang X, Chen J. Evaluation of visual function following neodymium: YAG laser posterior capsulotomy. Zhonghua Yan Ke Za Zhi 2002; 38(9): 556-61.
16. Mortazavi SA, Fatemeh E, Hosein A, Kobra N, Ghoreishi SM. Evaluation of Visual Function Improvement after Nd :YAG Laser Posterior Capsulotomy in Patient with Posterior Capsule Opacification. Journal of Isfahan Medical School 2008;26(88).
17. Claesson M, Klarén L, Beckman C, Sjöstrand J. Glare and contrast sensitivity before and after Nd:YAG laser capsulotomy. Acta Ophthalmol (Copenh). 1994 Feb;72(1):27-32.