

## Expression of P16 Tumor Marker in Cervical Cancer among Sudanese Women

MOHAMMED AHMAD NASER MUSTAFA

Faculty of Post Graduate  
AL-Neelain University, Khartoum, Sudan  
Dr. AGEEB MOHAMMED HASSAN  
Assistant Professor, Department of Pathology  
Sudan International University, Sudan

### Abstract:

*Background: Cervical cancer is one of the most common cancers affecting women worldwide. It is a malignant neoplasm arising from cell originating in the cervix uteri and it is the third most common gynecologic cancer diagnosis and cause of death among gynecologic cancers in the United States.*

*The current study aim is Immunohistochemical evaluation of p16, a tumor suppressor protein which plays an important role in cell cycle regulation in different types and grades of cervical cancer.*

*Methods: A total of 50 cases of formalin-fixed -paraffin embedded blocks of Sudanese female with cervical cancer were selected from archive of different histopathology laboratories. The Immunohistochemical staining with p16 was done on all cases.*

*Results: Immunohistochemistry of p16INK4A staining shows positive staining in 56% within grade III. 76% from cases were scored as (3+>75%) whereas 24% were scored as +2 (15%-20%). In correlation with age, high scored of P16 (+3) was prominent in the age group (31-60) comprising 40%. Total Percentage of P16 in age groups (1-30) was 12%, in (31-60) was 44% and in (61-90) was 44%.*

*Conclusion: p16 expression was strongly observed in cervical cancer but has no correlation with type and grade of cervical cancer*

**Key words:** P16 Tumor Marker, Cervical Cancer, Sudanese Women

## **INTRODUCTION:**

Cervical cancer is a malignant neoplasm arising from cell originating in the cervix uteri [1].

Cancer of the uterine cervix is the third most common gynecologic cancer diagnosis and cause of death among gynecologic cancers in the United States. Cervical cancer has lower incidence and mortality rates than uterine corpus and ovarian cancer, as well as many other cancer sites. [2]

Tobacco use, alcohol use, unhealthy diet, physical inactivity, sexually transmitted HPV-infection, infection by HBV, ionizing and non-ionizing radiation are the main cancer risk factors of cervical cancer. [3]

*P16* (also known as cyclin-dependent kinase inhibitor 2A, multiple tumor suppressor 1 and as several other synonyms), is a tumor suppressor protein, that in humans is encoded by the *CDKN2A* gene. *P16* plays an important role in cell cycle regulation by decelerating cells progression from G1 phase to S phase, and therefore acts as a tumor suppressor that is implicated in the prevention of cervical cancer. p16 can be used to improve the histological diagnostic accuracy of CIN3. The *CDKN2A* gene is frequently mutated or deleted in a wide variety of tumors. [4]

p16 is a widely used immunohistochemical marker in gynecologic pathology. Strong and diffuse cytoplasmic and nuclear expression of p16 in squamous cell carcinomas (SCC) of the female genital tract is strongly associated with high-risk human papilloma virus (HPV) infection and neoplasms of cervical origin. The majority of SCCs of uterine cervix express p16. [5]

Jiayinglin and others in 2014 suggested that p16 over expression is significantly associated with better prognosis.

## **MATERIALS AND METHODS:**

Fifty (50) formalin-fixed -paraffin embedded blocks of Sudanese female with cervical cancer were selected from archive of different histopathology laboratories in Khartoum state, collected samples was processed at Al-Yermouk college, immune staining was carried out at Radiation and Isotopes centre-khartoum (RICK). Evaluation of histopathology was made on 3 micron thick sections stained with hematoxylin and eosin, and the grading assessed by consultants Histopathologist using Nottingham grading system of Elston and Ellis (16).

**Immunohistochemistry:** Paraffin embedded blocks were cut at 3Mm and mounted on salinized slides, deparaffanization in xylene and then rehydrated through graded series of alcohol. Antigen retrieval was performed by using PT link, endogenous peroxidases activity was blocked with 3% hydrogen peroxide and methanol for 10 minutes, then incubated with 100\200 µL of primary antibody for p16 for 20 minutes at room temperature, rinsed in phosphate buffer saline, and binding of antibody was detected by incubating 20 minutes with detection system(Thermo - ultra vision) , finally, the sections were washed in three changes of PB , visualization of the positive reaction with 3,3 diaminobenzidine and counter-stained with hematoxylin.

The evaluation of the positive immunohistochemical reactions for p16INK 4a was semiquantitative (0 when there is no positive reaction, 1+ from 15%to 20% staining of the nuclei and cytoplasm, 2+from 25% to 75% and 3+>75%).

**Statistical analysis:** Frequency and cross tabulation was used during the statistical analysis using SPSS package version 18 and chi-square test was assessed to correlate between expression of P16 and tumor grade, type. Ethical clearance for this study is provided by ethical committee of Faculty of medical laboratory sciences –AL-Neelain University, Khartoum, Sudan.

## RESULTS

All the patients included in this study were females, with mean age 57 years. The histological diagnosis of cases included squamous cell carcinoma was (84%), adeno carcinoma (4%) and sarcoma (12%). The majority of cases About 56% within grade III. 76% from cases were scored as (3+>75%) whereas 24% were scored as +2 (15%-20%). Figure(1)

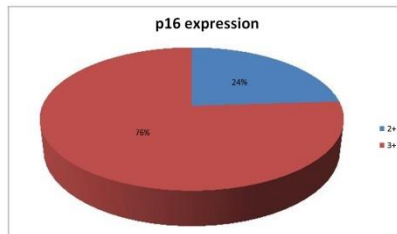
In correlation with age, high scored of P16 (+3) was prominent in the age group (31-60) comprising 40% (Table 1).

Total Percentage of P16 in age groups (1-30) was 12%, in (31-60) was 44% and in (61-90) was 44%.

In correlation with histological diagnosis, the expression of P16 was positive in all cases of cervical cancer. 64 % of squamous cell carcinoma scored +3, 20% were +2. Only 4% of adeno carcinoma scored +3. 8% of sarcoma scored +3 and 4% scored +2 showing that there is no correlation between p16 and type of cervical cancer with p.value:0.19 (Table 2)

In correlation with tumor grade, the expression of P16 has no correlation with p.value:0.13 (Table 3)

**Figure (1) Immunohistochemical expression of P16**



**Table (1) correlation between p16 and Age**

Age	P16 expression		Total
	25%-75%	>75%	
1-30	4%	8%	12%
31-60	4%	40%	44%

Mohammed Ahmad Naser Mustafa, Ageeb Mohammed Hassan- **Expression of P16 Tumor Marker in Cervical Cancer among Sudanese Women**

61-90	16%	28%	44%
Total	24%	76%	100%

p.value:0.20

**Table (2) correlation between p16 and Diagnosis**

P16 expression	Diagnosis			Total
	squamous cell carcinoma	adeno carcinoma	sarcoma	
25%-75%	20%	0%	4%	24%
>75%	64%	4%	8%	76%
Total	84%	4%	12%	100%

p.value:0.19

**Table (3) correlation between p16 and Tumor grade**

	grade I	grade II	grade III	not graded	Total
	25%-75%	0%	0%	20%	
>75%	8%	24%	36%	8%	76%
Total	8%	24%	56%	12%	100%

p.value:0.13

## DISCUSSION

S Nicolas and others in had found that 32 out of 46 of squamous cell carcinoma were scored as +3this similar to our findings.

In our study we found that the expression of p16 had no significant correlation with histopathological findings such as tumor type and grade, this finding same to Lin et al in 2014, they study association between P16 expression in cervical cancer tissue samples and several clinic pathological parameters and found that there is no correlation between P16 and tumor grade.

Buza and Tavassoli in 2009 had found that P16 immune reactivity is the same in carcinoma and sarcoma with no

significant differences, this is the same to our findings with p. value 0.19.

## **REFERENCE:**

- 1-Kumar V, Abbas AK, Fausto N, Mitchell RN (2007). Robbins Basic Pathology.
- 2-Siegel R, Ma J, Zou Z, Jemal A. Cancer statistics ( 2014) CA Cancer J Clin.
- 3- de Martel C, Ferlay J, Franceschi S, et al (2008) Global burden of cancers attributable to infections.
- 4- Stone S, Jiang P, Dayananth P, Tavtigian SV, Katcher H, Parry D, Peters G, Kamb A (July 1995). "Complex structure and regulation of the P16 (MTS1) locus".
- 5- Cioffi-Lavina M, Chapman-Fredricks J, Gomez-Fernandez C, Ganjei-Azar P, Manoharan M, Jorda M (2010). "P16 expression in squamous cell carcinomas of cervix and bladder.
- 6-Nicholas S, Constance M. 2003. p16 correlates with degree of cervical neoplasia : Acomprison with KI67 expression and detection of high risk HPVtypes. Modern pathology.16 ,7;665-673.
- 7- Jain Lin, Andreas E, Jainbo. 2014. Prognostic significance of over expressed P16 <sup>ink4a</sup> in patients with cervical cancer .Pols one . 9,9.
- 8- Buza N, Tavassoli F. 2009. Comparative analysis of P16 and P53 expression in uterine malignant mixed mullerian tumors. Gynological pathology. 28, 6; 514-521.